

UNIVERSIDADE DE SÃO PAULO  
FACULDADE DE ODONTOLOGIA DE BAURU

GONZALO PAÚL VELÁSQUEZ HUILCA

**Effects of a pre-fabricated corrector appliance in the early treatment  
of anterior crossbite in Class III malocclusion**

**Efeitos do aparelho corretor pré-fabricado no tratamento precoce  
da mordida cruzada anterior na má oclusão de Classe III**

BAURU

2021



GONZALO PAÚL VELÁSQUEZ HUILCA

**Effects of a pre-fabricated corrector appliance in the early treatment  
of anterior crossbite in Class III malocclusion**

**Efeitos do aparelho corretor pré-fabricado no tratamento precoce  
da mordida cruzada anterior na má oclusão de Classe III**

Dissertação constituída por artigo apresentada à Faculdade de Odontologia de Bauru da Universidade de São Paulo para obtenção do título de Mestre em Ciências no Programa de Ciências Odontológicas Aplicadas, na área de concentração Ortodontia.

Orientador: Prof. Dr. Guilherme Janson

**BAURU**

**2021**

Velásquez, Gonzalo

Effects of a pre-fabricated corrector appliance  
in the early treatment of anterior crossbite in Class  
III malocclusion – Bauru, 2021.

76p. : il. ; 31cm.

Dissertação de Mestrado – Faculdade de  
Odontologia de Bauru, Universidade de São  
Paulo.

Orientador: Prof. Dr. Guilherme Janson

Autorizo, exclusivamente para fins acadêmicos e científicos, a  
reprodução total ou parcial desta dissertação/tese, por  
processos fotocopiadores e outros meios eletrônicos.

Assinatura:

Data:

Comitê de Ética da FOB-USP  
Registro **CAAE: 24521419.6.0000.5417**  
Data: **12 de maio de 2020**

## ERRATA



## FOLHA DE APROVAÇÃO





---

---

## DEDICATÓRIA

Dedico este trabalho aos meus pais **Ana María** e **Cesar**, por seu exemplo de dedicação e trabalho, nunca mediram esforços para a minha formação. A sua presença me conforta e fortalece durante minha caminhada. A minha eterna gratidão e respeito.

---

---



---

---

## AGRADECIMENTOS

### Agradeço a **Deus**

Por me proteger e confortar nos momentos que precisei, por abençoar meu caminho e colocar em minha vida as pessoas certas, no lugar certo, no tempo certo.

---

---



---

---

Com carinho, agradeço especialmente,

À minha mãe **Ana Maria**, nunca poupou esforços em proporcionar tudo, mesmo quando estava longe de seu alcance. É um exemplo para mim. Serei eternamente grato pelo apoio e amor que recebi durante todos esses anos.

Ao meu pai **Cesar**, pelo amor incondicional, apoio e incentivo em benefício da minha formação humana e profissional, sempre torcendo para que meus objetivos se concretizassem, durante todo o tempo.

---

---



---

---

Ao meu irmão **Mauricio**, meu profundo a afeto pelo apoio, carinho e incentivo constantes.

A minha cunhada **Yanilet**, por ser parte importante da vida de meu irmão.

Aos meus queridos sobrinhos **Ignacio** e **Bastian**, pelo carinho e estímulo sempre presentes.

À minha família **Velásquez** e **Huilca**, pela paciência e compreensão da ausência e pelos momentos felizes mesmo longe de vocês.

Agradecimento especial à minha querida **Lena**, pelo carinho e companhia, ter conhecido você trouxe muito amor e alegria para minha vida. Ter você é amar sem pedir nada em troca, é aprender de tudo um pouco, é melhorar todos os dias como pessoa. Agradeço à Deus por ter colocado você em minha vida.

Aos meus professores da Universidade Católica de Santa María de Arequipa, que me ensinaram a base da Odontologia.

---

---





---

---

Meu profundo reconhecimento e admiração ao Professor Doutor **Guilherme Janson**, por sua competência e dedicação. Obrigado por os ensinamentos, por me fazer um aluno e ortodontista melhor, foi um grande privilégio ter sido seu orientado. Sou muito grato por compartilhar comigo seu enorme conhecimento, sempre exaltando a importância de uma Ortodontia baseada em evidência

Aos professores do Departamento de Ortodontia, Prof. Dr. **Arnaldo Pinzan**, Profa. Dra. **Daniela Gamba Garib**, Prof. Dr. **José Fernando Castanha Henriques**, Prof. Dr. **Marcos Roberto de Freitas**, Prof. Dr. **Renato Rodrigues de Almeida**. Obrigado por todos os ensinamentos transmitidos desde a especialização até chegar ao mestrado. Sempre terão meu carinho e respeito.

À minha querida turma de mestrado: **Demi Dahás**, **Henrique Eto**, **Jessica Quereza**, **Ronald Chuquimarca**, **Thales Lippi**, **Thagid Leal** e **Vinicius da Silva**. Muito grato com Deus por colocar vocês na minha vida, aprendi muito de cada um de vocês. Desejo a todos muito sucesso e obrigado pela amizade.

Agradecimento especial ao meu querido amigo **Henrique**, por todo o apoio brindado desde o primeiro dia do mestrado. Sou e serei muito grato pelos conselhos e os ensinamentos que você me deu. Você é uma grande pessoa e um melhor amigo.

Aos colegas do doutorado, em especial ao **Marcelo** e **Aron**, por sempre me orientar e ter uma vontade enorme de ensinar, sendo muito solidários e prestativos.

---

---



---

---

Aos colegas do doutorado novo e velho, por todas as orientações e apoio durante esses dois anos.

Aos funcionários do Departamento de Ortodontia: **Vera Purgato, Cléo Vieira, Sérgio Vieira, Wagner Baptista** e ao **Daniel Selmo**, obrigado por serem tão solícitos e nos ajudarem na realização deste curso de pós graduação.

Aos meus pacientes da FOB-USP, que foram fundamentais na minha formação profissional, obrigado pelo carinho e confiança.

À Faculdade de Odontologia de Bauru, Universidade de São Paulo, na pessoa da diretora Prof. Dr. **Carlos Ferreira dos Santos**, e do vice-diretor Prof. Dr. **Guilherme Janson**.

Ao **CNPq**, número de processo 133347/2019-2, pelo apoio financeiro e incentivo ao desenvolvimento da Ciência.

Finalmente quero agradecer à minha **banca examinadora** por aceitarem o convite de participação, ficarei atento das críticas e correções que farão deste um trabalho melhor.

---

---



# ABSTRACT

---

---



---

---

## ABSTRACT

### **Effects of a pre-fabricated corrector appliance in the early treatment of anterior crossbite in Class III malocclusion**

**Introduction:** In Class III malocclusion, interception in the deciduous and mixed dentitions is of clinical interest, because of the limited possibilities of intervention. Recently, a pre-fabricated appliance has been developed to correct Class III malocclusions in the deciduous and mixed dentitions. However, the effects of this device have not been studied and described in the literature. **Objective:** The aim of the present prospective study was to cephalometrically evaluate the effects and to assess the effectiveness and clinical performance of the Ortho-Tain Class III Corrector Appliance in the early correction of anterior crossbite in Class III malocclusion. **Methods:** The sample consisted of 2 groups. The experimental group comprised 22 patients treated with the Ortho-Tain Class III Corrector Appliance, during a mean period of 20. The control group comprised 22 untreated subjects with Class III malocclusion with or without anterior crossbite who presented lateral cephalograms. Intergroup comparison of treatment and normal growth changes were compared with t and Mann-Whitney tests. **Results:** There was a significant difference in the mandibular plane angle changes because it decreased in the treated patients and increased in the control group. Additionally, the lower anterior face height increase and maxillary molar vertical development were significantly smaller in the treatment group. There was a significant decrease in the number of patients with anterior crossbite and edge-to-edge relationships, during treatment, in the experimental group. **Conclusions:** This appliance produced counter-clockwise rotation of the mandibular plane, smaller lower anterior face height increase and maxillary molar vertical development, improvement of anterior crossbite in 75% of the patients and therefore, it is an important alternative for early Class III malocclusion treatment.

**Keywords:** Class III malocclusion, anterior cross bite, Ortho-Tain Class III Corrector Appliance, early treatment

---

---





# RESUMO

---

---



---

---

## RESUMO

### **Efeitos do aparelho corretor pré-fabricado no tratamento precoce da mordida cruzada anterior na má oclusão de Classe III**


**Introdução:** Na má oclusão de Classe III, a interceptação na dentição decídua e mista é de interesse clínico, devido às possibilidades limitadas de intervenção. Recentemente, um aparelho pré-fabricado foi desenvolvido para corrigir as más oclusões de Classe III nas dentições decídua e mista. No entanto, os efeitos desse dispositivo não foram estudados e descritos na literatura. **Objetivo:** O objetivo do presente estudo prospectivo foi avaliar cefalometricamente os efeitos, a eficácia e o desempenho clínico do aparelho corretor Ortho-Tain Classe III na correção precoce da mordida cruzada anterior na má oclusão de Classe III. **Métodos:** A amostra foi composta por 2 grupos. O grupo experimental foi composto por 22 pacientes tratados com o aparelho corretor Ortho-Tain Classe III, durante um período médio de 20 meses. O grupo controle foi composto por 22 indivíduos não tratados com má oclusão de Classe III com ou sem mordida cruzada anterior que apresentavam telerradiografias laterais. A comparação intergrupo do tratamento e as mudanças normais de crescimento foram comparadas com os testes t e Mann-Whitney. **Resultados:** Houve diferença significativa nas alterações do ângulo do plano mandibular, pois diminuiu nos pacientes tratados e aumentou no grupo controle. Além disso, o aumento da altura facial anterior inferior e o desenvolvimento vertical dos molares superiores foram significativamente menores no grupo de tratamento. Houve diminuição significativa do número de pacientes com mordida cruzada anterior e relação borda a borda, durante o tratamento, no grupo experimental. **Conclusões:** Este aparelho produziu rotação anti-horária do plano mandibular, menor aumento da altura facial anterior inferior e desenvolvimento vertical dos molares superiores, melhora da mordida cruzada anterior em 75% dos pacientes e, portanto, é uma alternativa importante para o tratamento precoce da má oclusão de Classe III.

**Palavras-chave:** Má oclusão de Classe III, mordida cruzada anterior, aparelho corretor Ortho-Tain Classe III, tratamento precoce.

---


---





## LIST OF ILLUSTRATIONS

- Figure 1** Class III Corrector Appliance.<sup>1</sup> A, front view; B, posterior front view; C, right side view; D, left side view; E, top view; F, bottom view..... 38
- Figure 2** Pretreatment and posttreatment facial and intraoral photographs of a patient treated with the Class III Corrector Appliance (after 12 months of treatment)..... 39
- Figure 3** Cephalometric superimpositions of the initial and final mean tracings of the experimental group: black line, pretreatment; red line, posttreatment..... 40
- Figure 4** Cephalometric superimpositions of the initial and final mean tracings of the control group: black line, pretreatment; red line, posttreatment..... 41



## LIST OF TABLES

<b>Table I:</b>	Definitions of the cephalometric variables used .....	42
<b>Table II:</b>	Intergroup comparison of initial and final ages, period of evaluation, sex and anterior teeth relationships distribution .....	43
<b>Table III:</b>	Intergroup comparison of the initial cephalometric characteristics .....	44
<b>Table IV:</b>	Intragroup treatment changes of the experimental group .....	45
<b>Table V:</b>	Intragroup normal growth changes of the control group.....	46
<b>Table VI:</b>	Intergroup comparison between treatment changes and normal growth .....	47
<b>Table VII:</b>	Intragroup and intergroup comparisons of the proportions of Anterior Crossbite (ACB), Edge-to-Edge and normal overjet at T1 and T2 (McNemar and Chi-square tests) .....	48



---

---

---

---

## LIST OF ABBREVIATIONS AND ACRONYMS

<b>ACB</b>	Anterior crossbite
<b>T1</b>	Timing 1
<b>T2</b>	Timing 2
<b>AAOF</b>	American Association of Orthodontists Foundation

---

---

---

---

## TABLE OF CONTENTS

1	INTRODUCTION.....	17
2	ARTICLE.....	21
3	DISCUSSION.....	51
4	CONCLUSION .....	57
	REFERENCES.....	61
	APPENDIX .....	67
	ANNEXES .....	71

---

---

---

---

# **1 INTRODUCTION**

---

---







## 1 INTRODUCTION

Malocclusions are the result of multiple genetic and environmental factors, and during development of the dentition, primary occlusion may improve or often worsen when the child transitions from the primary to permanent dentition.(VEDOVELLO; DE CARVALHO; DE AZEVEDO; SANTOS *et al.*, 2020) Mixed dentition is a transitional stage, characterized by a wide range of occlusal variations(TAUSCHE; LUCK; HARZER, 2004) and a high prevalence of malocclusion.

To avoid early functional and psychological harm, assessment of the occlusion in the mixed dentition is essential. This malocclusions have negative effects on children's and adolescent's oral health related quality of life.(VEDOVELLO; DE CARVALHO; DE AZEVEDO; SANTOS *et al.*, 2020)

Although early treatment is suggested to bring about many benefits including better use of the patient's growth potential, reduced need of extractions and orthognathic surgery, lesser risk for adverse iatrogenic effects, better patient compliance, and better and more stable results, many clinicians express skepticism and point out that the effectiveness of early treatment is not corroborated by hard scientific evidence.(KESKI-NISULA; LEHTO; LUSA; KESKI-NISULA *et al.*, 2003)

Class III malocclusion is characterized by anteroposterior dental discrepancy and anterior positioning of the mandible in relation to the cranium base and/or maxilla, affecting between 5% and 15% of the population.(AL-MOZANY; DALCI; ALMUZIAN; GONZALEZ *et al.*, 2017; LI; CAI; CHEN; CHEN, 2016) This discrepancy may be caused by anteroposterior maxillary deficiency, mandibular protrusion, or a combination of both.(MARTINA; D'ANTÒ; DE SIMONE; GALEOTTI *et al.*, 2020) The main features of Class III malocclusion with anterior crossbite are mainly the concave profile caused by deficiency of the middle third of the face, the absence of prominence of the zygomatic bone and the excess of the lower third of the face.(OLTRAMARI-NAVARRO; DE ALMEIDA; CONTI; NAVARRO RDE *et al.*, 2013)

Anterior crossbite refers to malocclusion resulting from lingual position of maxillary anterior teeth in relationship to the mandibular anterior teeth.(VASILAKOS; KONIARIS; WOLF; HALAZONETIS *et al.*, 2018) Anterior crossbite is established in

---

---

the mixed dentition (BORRIE; BEARN, 2011; WIEDEL; BONDEMARK, 2015) and is one form of malocclusion requiring early treatment. (TAUSCHE; LUCK; HARZER, 2004)

Among the main therapeutic options for the correction of this malocclusion, we can mention the facial mask therapy and the use of the chin cup during growth, (MANDALL; DIBIASE; LITTLEWOOD; NUTE *et al.*, 2010; MARTINA; D'ANTÒ; DE SIMONE; GALEOTTI *et al.*, 2020; SMYTH; RYAN, 2017) associated or not with a previous rapid maxillary expansion. (CHA, 2003; MARTINA; D'ANTÒ; DE SIMONE; GALEOTTI *et al.*, 2020; MOON; AHN; CHANG, 2005; SOUKI; NIERI; PAVONI; PAVAN BARROS *et al.*, 2020; VAUGHN; MASON; MOON; TURLEY, 2005; WATKINSON; HARRISON; FURNESS; WORTHINGTON, 2013) Another option is the Fränkel appliance “function regulator” for Class III. (YANG, 1996; YANG; LI; BAI; SU *et al.*, 2014)

The literature reports that some works have been developed using the eruption guidance appliance, prefabricated devices and traditionally used in deep overbite Class I or II malocclusion, but not for class III. (BERGERSEN, 1984; JANSON; NAKAMURA; CHIQUETO; CASTRO *et al.*, 2007; JANSON; DA SILVA; BERGERSEN; HENRIQUES *et al.*, 2000; MYRLUND; KESKI-NISULA; KEROSUO, 2019) Although the eruption guidance appliance is not designed for Class III treatment, there are reported cases in patients with anterior crossbite that demonstrate that it promotes improved dental positioning in the anterior region. (PELLEGRINO; CARUSO; CANTILE; PELLEGRINO *et al.*, 2020)

Thus, the aim of the present prospective study was to assess the effectiveness, and clinical performance of this simple method early correction of class III malocclusion associated with anterior crossbite.

# **2 ARTICLE**

---

---



## **2 ARTICLE**

The article presented in this Dissertation was formatted according to the American Journal of Orthodontics and Dentofacial Orthopedics instructions and guidelines for article submission.

## EFFECTS OF A PRE-FABRICATED CORRECTOR APPLIANCE IN THE EARLY TREATMENT OF ANTERIOR CROSSBITE IN CLASS III MALOCCLUSION

### ABSTRACT

**Introduction:** In Class III malocclusion, interception in the deciduous and mixed dentitions is of clinical interest, because of the limited possibilities of intervention. Recently, a pre-fabricated appliance has been developed to correct Class III malocclusions in the deciduous and mixed dentitions. However, the effects of this device have not been studied and described in the literature. **Objective:** The aim of the present prospective study was to cephalometrically evaluate the effects and to assess the effectiveness and clinical performance of the Ortho-Tain Class III Corrector Appliance in the early correction of anterior crossbite in Class III malocclusion. **Methods:** The sample consisted of 2 groups. The experimental group comprised 22 patients treated with the Ortho-Tain Class III Corrector Appliance, during a mean period of 20 months. The control group comprised 22 untreated subjects with Class III malocclusion with or without anterior crossbite who presented lateral cephalograms. Intergroup comparison of treatment and normal growth changes were compared with t and Mann-Whitney tests. **Results:** There was a significant difference in the mandibular plane angle changes because it decreased in the treated patients and increased in the control group. Additionally, the lower anterior face height increase and maxillary molar vertical development were significantly smaller in the treatment group. There was a significant decrease in the number of patients with anterior crossbite and edge-to-edge relationships, during treatment, in the experimental group. **Conclusions:** This appliance produced counter-clockwise rotation of the mandibular plane, smaller lower anterior face height increase and maxillary molar vertical development, improvement of anterior crossbite in 75% of the patients and therefore, it is an important alternative for early Class III malocclusion treatment.

**Keywords:** Class III malocclusion, anterior cross bite, Ortho-Tain Class III Corrector Appliance, early treatment.

---

---

## INTRODUCTION

Class III malocclusion is the result of multiple genetic and environmental factors during development of the dentition and patients with discrepancies in occlusion require early intervention to avoid functional and psychological harm.<sup>1,2</sup> This malocclusion is characterized by anteroposterior dental discrepancy and anterior positioning of the mandible in relation to the cranial base and/or maxilla, affecting between 5% and 15% of the population.<sup>3,4</sup> This discrepancy may be caused by anteroposterior maxillary deficiency, mandibular protrusion, or a combination of both.<sup>5</sup> When it is essentially skeletal in origin, this malocclusion produces a marked facial deformity.<sup>3,4,6</sup>

The main features of Class III malocclusion with anterior crossbite are the concave profile caused by deficiency of the middle third of the face, the absence of prominence of the zygomatic bone and the excess of the lower facial third.<sup>7</sup>

Anterior crossbite refers to malocclusion resulting from lingual positioning of the maxillary anterior teeth in relation to the mandibular anterior teeth.<sup>8</sup> The reported prevalence of anterior crossbite in the mixed dentition varies between 1.6% and 7.9%.<sup>8</sup>

According to its origin, it can be differentiated into skeletal and dental crossbite. Skeletal crossbite is associated with a concave skeletal and soft tissue profile and usually requires more extensive interventions to be managed. Dental or dentoalveolar anterior crossbite is a more localized problem and more easily managed.<sup>8</sup> This is established in the mixed dentition<sup>9,10</sup> and can lead to adverse complications including: damage to the teeth in crossbite through attrition, gingival recession and loss of alveolar bone support of the mandibular incisor, temporomandibular joint disorders,<sup>11</sup> mobility of the mandibular incisor affected by the crossbite, potential adverse growth influences on the mandible and the anterior portion of the maxilla, as well as facial disharmony.<sup>9,12</sup> Therefore, it is highly recommended to correct an anterior crossbite in the deciduous or early mixed dentition to allow normal development of the occlusion.<sup>12</sup>

On the other hand, Class III treatment time, as well as its stability are very important aspects in an early approach. However, there is a lack of evidence regarding the long-term benefits of this intervention.<sup>13,14</sup> Class III malocclusion can be intercepted during the craniofacial growth and development phase through the use of orthopedic appliances, which act predominantly on the maxilla.<sup>15</sup>

---

In Class III malocclusion, interception in the deciduous and mixed dentitions is of clinical interest, because of the limited possibilities of intervention.<sup>4</sup> Among the main therapeutic options for correction of this malocclusion, are the facial mask and the use of a chin cup during growth,<sup>5,16,17</sup> associated or not with previous rapid maxillary expansion.<sup>5,13,18-21</sup> Another option is the Fränkel “function regulator” for Class III malocclusion.<sup>22,23</sup> Therefore, two of the most influential factors in the treatment plan of this malocclusion are the timing of the intervention and the malocclusion severity. When its nature is predominantly dentoalveolar, whether or not associated with anterior crossbite, its treatment is simplified as it is based on correction of the dentoalveolar positioning. This type of correction can be performed with devices such as removable protrusion spring plates, the Fränkel Class III appliance,<sup>22,23</sup> and the Bionator for Class III malocclusions.<sup>24</sup>

Pre-fabricated functional appliances have been developed to correct Class I and II malocclusions and their effects have been reported.<sup>25-31</sup> Recently, a pre-fabricated appliance has been developed to correct Class III malocclusions in the deciduous and mixed dentitions.<sup>32</sup> However, the effects of this device have not been studied and described in the literature.

Thus, the aim of the present prospective study was to cephalometrically evaluate the effects and to assess the effectiveness and clinical performance of this appliance in the early correction of Class III malocclusion, associated with anterior crossbite.

## **MATERIAL AND METHODS**

This study was approved by the Ethics in Research Committee of Bauru Dental School, University of São Paulo, Brazil (protocol number, 24521419.6.0000.5417) and all subjects signed informed consent.

Sample size calculation showed that, to detect a minimum intergroup difference of 2 mm, with a standard deviation of 2.3 mm, in the overjet, at a significance level of 5% and with a test power of 80%, 22 patients would be necessary in each group.<sup>5</sup> Consecutively treated patients, which met the inclusion criteria, were selected at the Orthodontic Clinic of Bauru Dental School, University of São Paulo, Brazil, during May 2017 to April 2019. Subjects with ages ranging from 6 to 9 years, with Class III malocclusion, anterior crossbite, end of the early mixed dentition and without previous orthodontic treatment were included. Subjects with

---



previous orthodontic treatment, craniofacial or dental anomalies and syndromes, were excluded.

The sample consisted of 2 groups, one experimental and the other control, with Class III malocclusion associated or not with an anterior crossbite.

The experimental group comprised 22 patients (12 male, 10 female, with a mean age of  $7.63 \pm 0.96$  years) treated with the Ortho-Tain Class III Corrector Appliance,<sup>32</sup> during a mean period of  $1.72 \pm 0.48$  years (20 months). Sixteen had an anterior crossbite, and 6 had an edge-to-edge incisor relationship. Each patient was instructed to use the appliance while sleeping and for four hours during daytime. The patient had to use the appliance for 4 continuous hours, always keeping the lips in contact, without talking or playing with the device. The patient was instructed to insert the appliance according to the instructional arrow which points upward to the maxilla.

The child had to be exercising by pushing the tongue against the three tabs that are located in the upper portion, directly behind the anterior teeth, pressing the maxillary arch in a forward direction as hard as they can against all three tabs. This tongue movement and pressure will encourage the maxilla to move in a forward direction as well as the mid-face to move forward. Treatment was considered as concluded when Class I molar relationship and at least a 0 mm overjet was achieved.

The control group comprised 22 subjects (12 male, 10 female, with a mean age of  $7.21 \pm 0.60$  years). Because the files of the orthodontic department comprised only 5 untreated subjects with Class III malocclusion with anterior crossbite, who presented lateral cephalograms taken at the period, a convenience sample was obtained from the American Association of Orthodontists Foundation (AAOF) Craniofacial Growth Legacy Collection Website.<sup>33</sup> From the 35 AAOF online available subjects who fit the selection criteria, 17 were selected presenting high quality headfilm images. Therefore, the sample consisted of these subject records associated with the records of the 5 subjects from the files of the Orthodontic Department at Bauru Dental School. Eight had an anterior crossbite, 7 had an edge-to-edge incisor relationship and 7 had a normal overjet.

Lateral cephalometric radiographs were obtained of each patient at the pretreatment (T1) and posttreatment (T2) stages. The radiographs were digitized and analyzed with *Dolphin*<sup>®</sup> Imaging 11.9 software (Dolphin Imaging & Management Solutions, Chatsworth, Calif). Points and reference lines were traced by a calibrated operator (G.P.V.H. Table I).

---



### **Error study**

Thirty days after the first measurement, ten randomly selected radiographs were retraced and remeasured by the same calibrated examiner (G.P.V.H.). Random errors were calculated with Dahlberg's formula,<sup>34</sup> ( $S^2 = \sum d^2 / 2n$ ) where  $S^2$  is the error variance and  $d$  is the difference between 2 determinations of the same variable. Systematic errors were evaluated with dependent t tests,<sup>35</sup> at  $P < 0.05$ .

### **Statistical analyses**

Normal distribution was assessed with Shapiro-Wilk tests. Intergroup comparability regarding initial and final ages, period of evaluation, and sex distribution, were assessed with t, Mann-Whitney and Chi-square tests, respectively. Intergroup comparison of the initial cephalometric characteristics was performed with t and Mann-Whitney tests. Intragroup treatment and normal growth changes were evaluated with dependent t and Wilcoxon tests. Intergroup comparison of treatment and normal growth changes were compared with t and Mann-Whitney tests.

The percentage of patients with anterior crossbite, edge-to-edge incisor relationship and normal overbite were compared within and between the groups with McNemar and chi-square tests, respectively. In the intragroup comparisons, the anterior crossbite and edge-to-edge patients were grouped together as "abnormal overjet" to allow a 2x2 table comparison.

All statistical analyses were performed using Statistica software (Statistica for Windows, version 7.0, StatSoft Inc., Tulsa, Okla., USA), at  $P < 0.05$ .

## **RESULTS**

The random errors ranged from 0.22 mm (Md1-MP) to 2.12 mm (Pg-Nperp) and from 0.35° (ANB) to 2.92° (NLA) for linear and angular measurements, respectively, and were within acceptable limits.<sup>36</sup> Significant systematic errors were found for variables Mx6-PP, Mx6-Ptv and Md1-NB.

The groups were similar regarding initial and final ages, period of evaluation and sex distribution (Table II).

At the pretreatment stage (T1), the experimental group presented significantly shorter maxillary effective length and greater maxillary retrusion, and significantly greater maxillary molar posterior height and distal positioning, than the control group (Table III). The mandibular incisors were significantly more labially tipped and

---

protruded and the first molars were more distally positioned in the experimental than in the untreated subjects. Overbite was significantly greater and overjet smaller, in the experimental group. The experimental group also presented significantly smaller nasolabial angle, more retruded upper lip and more protruded lower lip than the control group.

With treatment, the experimental group presented significant increases in maxillary and mandibular effective lengths, mandibular protrusion and maxillomandibular differential, and decreases in maxillomandibular relationship (ANB) and skeletal profile concavity (Table IV). There was significant counterclockwise rotation of the mandibular and occlusal planes, and a significant increase in lower anterior face height. The maxillary incisors had significant labial tipping, protrusion and vertical development, and the molars experienced vertical development and mesialization. Simultaneously, there were significant protrusion, vertical development and labial tipping of the mandibular incisors, and vertical development and mesialization of the molars. Additionally, there was significant increase in the overjet and in the soft profile convexity.

During the same time interval, the control group presented significant increases in maxillary and mandibular lengths, and in the maxillomandibular difference, and a significant decrease in the skeletal Class III discrepancy (Wits – Table V). There was significant decrease of the occlusal plane angle and a significant increase of the lower anterior face height. The maxillary and mandibular incisors showed significant labial tipping, protrusion and vertical development, and the maxillary and mandibular molars experienced vertical development and mesialization. There was significant increase in the overjet and in the soft profile convexity.

Intergroup changes comparison showed that there was a significant difference in the mandibular plane angle changes because it decreased in the treated patients and increased in the control group (Table VI). Additionally, the lower anterior face height increase and maxillary molar vertical development were significantly smaller in the treatment group.

At the end of treatment, the experimental group presented significantly smaller number of patients with anterior crossbite and edge-to-edge relationships than at the pre-treatment stage (Table VII). The experimental group presented significantly greater number of patients with anterior crossbite and smaller number of patients with

---

normal overjet than the control group at the pre-treatment stage. At the end of the evaluation period, both groups presented similar proportions of patients with anterior crossbite, edge-to-edge incisor relationship and normal overbite.

## **DISCUSSION**

### **Sample**

According to the sample size calculation, 22 patients should comprise each group, the experimental and the control. Even though this may be considered a small group, one has to consider that Class III malocclusion is the least prevalent in the population, with a mean prevalence between 5% and 15%.<sup>3,4</sup> Additionally, the patients should all fulfil the inclusion criteria, which restricted even more the number of available patients. Therefore, having 22 Class III patients to be evaluated may be considered very satisfactory.

Finding a matching control group was also another difficult task. The Orthodontic Department has a normal growth sample consisting of 256 subjects, followed from 3 to 18 years of age. However, among these subjects only 5 fulfilled the inclusion criteria. Therefore, it was necessary to resort to the American Association of Orthodontists Foundation (AAOF) Craniofacial Growth Legacy Collection.<sup>33</sup> to complete the required minimum of 22 subjects.

The groups were similar regarding the initial and final ages, period of evaluation, and sex distribution (Table II). However, despite all efforts, the experimental group had a significantly greater number of patients with anterior crossbite at pretreatment, and among 32 variables, there were significant differences among 13 cephalometric variables. The experimental group had a significantly smaller maxillary effective length and consequently greater retrusion of the maxilla (Table III). Maxillary dentoalveolar height was larger in the treated group and the first molar was more distally positioned. The mandibular incisors were more labially tipped and protruded, molar dentoalveolar height was smaller, overbite was greater and the overjet was smaller in the experimental group. Finally, the nasolabial angle was smaller, the upper lip was more retruded and the lower lip more protruded in the treated group. Summarizing, these differences demonstrate that the Class III characteristics were more accentuated in the experimental group. Ideally, the groups should show more similar characteristics. However, sometimes this is extremely difficult and it is better to have a satisfactory control group than no control at all.<sup>37</sup>

---

Besides, the most important aspects to be evaluated are the changes that occurred with treatment and not the final cephalometric characteristics.

### **Tracings**

Because 6 patients (27% of the sample) presented the deciduous incisors at pretreatment, they were traced in the initial cephalogram. At the end of the evaluation period, these patients already had their permanent maxillary incisors, which were traced in the final cephalogram. This procedure may be criticized; however, we think that it is the best way to represent what actually occurred. The appliance began acting on the deciduous incisors, and when they were exfoliated and the permanent incisors erupted, it continued to act on the permanent incisors. Consequently, whatever effect was produced can be visualized in the permanent incisors. Besides, the control group also had 10 patients (45%) in the same condition as the experimental group, matching the groups regarding this aspect.

### **Treatment changes**

#### **Maxillomandibular relationships**

Most of the treatment changes were similar to normal growth changes (Tables IV to VI). There were significant increases in maxillary and mandibular effective lengths and in the maxillomandibular differential, therefore increasing the skeletal Class III discrepancy. This was also discretely shown by the ANB. Therefore, it seems that the appliance did not have a skeletal effect in the skeletal Class III relationship. These effects are similar to the Frankel FRIII appliance in Class III malocclusion correction.<sup>23</sup> Usually, Class III removable functional appliances have limited effects in correction of skeletal Class III discrepancies.<sup>38</sup> Maxillary expansion followed by face masks usually present a skeletal effect in Class III malocclusion correction at a similar age range.<sup>39-41</sup> However, the forces applied are delivered by elastics and are considered to be in the orthopedic range.<sup>42</sup> Additionally, face masks are extraoral appliances and are very unattractive.<sup>40,41</sup>

#### **Vertical relationships**

The major effects of the appliance were in the vertical relationships (Tables IV to VI). It was able to produce a decrease in the mandibular plane angle, which was significantly different from normal growth, increasing this angle. Additionally, it also

---

significantly restricted the increase of the lower anterior face height. These effects may be consequent to the occlusal shelves of the appliance that can cause some restriction in vertical development of the posterior teeth.<sup>29</sup> This was clearly shown by the significantly smaller vertical development of the maxillary first molars (Table VI). This effect is opposite to the effects of the Frankel FRIII and to the face mask that usually tend to increase the mandibular plane angle and the lower anterior face height, causing a clockwise mandibular rotation.<sup>14,22</sup> Therefore, it is mostly useful in patients with a vertical growth pattern.

### **Maxillary and mandibular dentoalveolar components**

The appliance did have an effect in correcting the anterior crossbite by labially tipping and protruding the maxillary incisors (Tables IV to VI). Nevertheless, these changes were not significantly greater than normal growth. This is probably because the maxillary deciduous incisors are more vertically positioned than the maxillary permanent incisors. Consequently, as the permanent maxillary incisors erupt, they already do it, with a greater labial inclination than their former deciduous incisors. Therefore, no significant intergroup differences were observed. Similar effects were observed for the Frankel FRIII appliance.<sup>22</sup> On the other hand, the face mask is able to significantly labially tip and protrude the maxillary incisors, beyond the capability of normal growth.<sup>14</sup>

As previously mentioned, there was vertical development restriction of the maxillary first molars, probably due to the posterior occlusal shelves of the appliance. These teeth also had some mesial movement, which contributes to Class III correction. However, it was not significantly greater than normal growth.

Changes in the mandibular incisors consisted in labial tipping, protrusion and vertical development, and in the mandibular molars, they consisted in vertical development and mesialization, which were all similar to normal growth. Therefore, the appliance appears to have had no significant effects in the mandibular dentoalveolar components.

### **Dentoalveolar relationships and soft tissue profile**

The significant intragroup changes in the maxillary incisors of the treated group contributed to the significant improvement of the overjet in the group (Tables IV and VI). Nevertheless, consequent to the similar changes in the foreseen

---

cephalometric variables, there were no significant intergroup differences in overbite, overjet and molar relationship. Effects of the Frankel FRIII are similar to these effects.<sup>22</sup> On the other hand, the facemask demonstrated significant improvement in overjet and molar relationship, when compared to normal growth changes.<sup>14</sup>

Likewise, a similar interpretation applies to the soft tissue profile variables.

### **Anterior crossbite**

Despite there were only small treatment changes in the intergroup comparisons in the cephalometric variables, the amount of patients with anterior crossbite in the treated group decreased significantly between the pre- and posttreatment stages in the treated group, while it did not happen in the control group (Table VII). Additionally, while the percentage of patients in the treated groups was significantly greater in the initial stage, than in the control group, it became similar in the posttreatment stage. There was improvement of anterior crossbite in 12 of the 16 patients (75%) that originally had a complete anterior crossbite and there was correction of anterior cross-bite or edge to edge anterior occlusion in 12 of the original 22 patients (54.54%) that presented these problems. This demonstrates the efficiency of the appliance in correcting the anterior crossbite.

Although the cephalometric results demonstrated minimum effects of this appliance, evaluation of anterior crossbite correction demonstrated very satisfactory results of the appliance effects. Because it is an intraoral appliance and very esthetic it can be a very important alternative for early Class III malocclusion treatment.

Treatment of some of these patients was somewhat compromised by the Covid-19 pandemic. In March 2020, 12 patients (55%) had already finished treatment. However, 10 were still under treatment and could not be monthly followed due to lockdown of the Dental School Clinics. They were remotely monitored by the student in charge of this investigation. In October 2020, when some clinical investigations, that were in their final stage, were allowed to return, the patients were recalled to continue treatment and have their final records taken. This may have had some impact in the results.

---



## **CONCLUSIONS**

- The Ortho-Tain Class III corrector appliance produced counter-clockwise rotation of the mandibular plane, smaller lower anterior face height increase and maxillary molar vertical development;
- Improvement of anterior cross-bite in 75% of the patients;
- Correction of anterior cross-bite or edge to edge anterior occlusion in 54.54% of the patients;
- The Ortho-Tain Class III corrector appliance is an important alternative for early Class III malocclusion treatment.

## **Acknowledgment:**

We would like to thank the National Council of Research (CNPq) for the financial support.

---

---

**REFERENCES**

1. Tausche E, Luck O, Harzer W. Prevalence of malocclusions in the early mixed dentition and orthodontic treatment need. *Eur J Orthod* 2004;26:237-244.
  2. Vedovello SAS, de Carvalho ALM, de Azevedo LC, Santos PRD, Vedovello-Filho M, Meneghim MC. Impact of anterior occlusal conditions in the mixed dentition on oral health-related quality-of-life item levels: A multivariate analysis. *Angle Orthod* 2020.
  3. Al-Mozany SA, Dalci O, Almuzian M, Gonzalez C, Tarraf NE, Ali Darendeliler M. A novel method for treatment of Class III malocclusion in growing patients. *Prog Orthod* 2017;18:40.
  4. Li C, Cai Y, Chen S, Chen F. Classification and characterization of class III malocclusion in Chinese individuals. *Head Face Med* 2016;12:31.
  5. Martina R, D'Antò V, De Simone V, Galeotti A, Rongo R, Franchi L. Cephalometric outcomes of a new orthopaedic appliance for Class III malocclusion treatment. *Eur J Orthod* 2020;42:187-192.
  6. Ngan P, Moon W. Evolution of Class III treatment in orthodontics. *Am J Orthod Dentofacial Orthop* 2015;148:22-36.
  7. Oltramari-Navarro PV, de Almeida RR, Conti AC, Navarro Rde L, de Almeida MR, Fernandes LS. Early treatment protocol for skeletal Class III malocclusion. *Braz Dent J* 2013;24:167-173.
  8. Vasilakos G, Koniaris A, Wolf M, Halazonetis D, Gkantidis N. Early anterior crossbite correction through posterior bite opening: a 3D superimposition prospective cohort study. *Eur J Orthod* 2018;40:364-371.
  9. Borrie F, Bearn D. Early correction of anterior crossbites: a systematic review. *J Orthod* 2011;38:175-184.
  10. Wiedel AP, Bondemark L. Stability of anterior crossbite correction: a randomized controlled trial with a 2-year follow-up. *Angle Orthod* 2015;85:189-195.
  11. Thilander B, Rubio G, Pena L, de Mayorga C. Prevalence of temporomandibular dysfunction and its association with malocclusion in children and adolescents: an epidemiologic study related to specified stages of dental development. *Angle Orthod* 2002;72:146-154.
  12. Khalaf K, Mando M. Removable appliances to correct anterior crossbites in the mixed dentition: a systematic review. *Acta Odontol Scand* 2020;78:118-125.
-

13. Moon YM, Ahn SJ, Chang YI. Cephalometric predictors of long-term stability in the early treatment of Class III malocclusion. *Angle Orthod* 2005;75:747-753.
  14. Woon SC, Thiruvengkatachari B. Early orthodontic treatment for Class III malocclusion: A systematic review and meta-analysis. *Am J Orthod Dentofacial Orthop* 2017;151:28-52.
  15. Rongo R, D'Antò V, Bucci R, Polito I, Martina R, Michelotti A. Skeletal and dental effects of Class III orthopaedic treatment: a systematic review and meta-analysis. *J Oral Rehabil* 2017;44:545-562.
  16. Mandall N, DiBiase A, Littlewood S, Nute S, Stivaros N, McDowall R et al. Is early Class III protraction facemask treatment effective? A multicentre, randomized, controlled trial: 15-month follow-up. *J Orthod* 2010;37:149-161.
  17. Smyth RSD, Ryan FS. Early treatment of class III malocclusion with facemask. *Evid Based Dent* 2017;18:107-108.
  18. Cha KS. Skeletal changes of maxillary protraction in patients exhibiting skeletal class III malocclusion: a comparison of three skeletal maturation groups. *Angle Orthod* 2003;73:26-35.
  19. Souki BQ, Nieri M, Pavoni C, Pavan Barros HM, Junqueira Pereira T, Giuntini V et al. Development and validation of a prediction model for long-term unsuccess of early treatment of Class III malocclusion. *Eur J Orthod* 2020;42:200-205.
  20. Vaughn GA, Mason B, Moon HB, Turley PK. The effects of maxillary protraction therapy with or without rapid palatal expansion: a prospective, randomized clinical trial. *Am J Orthod Dentofacial Orthop* 2005;128:299-309.
  21. Watkinson S, Harrison JE, Furness S, Worthington HV. Orthodontic treatment for prominent lower front teeth (Class III malocclusion) in children. *Cochrane Database Syst Rev* 2013:Cd003451.
  22. Yang KH. Frankel appliance type III: correct fabrication and case report of skeletal Class III malocclusion. *J Clin Pediatr Dent* 1996;20:281-292.
  23. Yang X, Li C, Bai D, Su N, Chen T, Xu Y et al. Treatment effectiveness of Fränkel function regulator on the Class III malocclusion: a systematic review and meta-analysis. *Am J Orthod Dentofacial Orthop* 2014;146:143-154.
  24. Giancotti A, Maselli A, Mampieri G, Spanò E. Pseudo-Class III malocclusion treatment with Balters' Bionator. *J Orthod* 2003;30:203-215.
-

25. Bergersen EO. The eruption guidance myofunctional appliances: how it works, how to use it. *Funct Orthod* 1984;1:28-29, 31-25.
  26. Janson G, de Souza JE, de Freitas MR, Henriques JF, Cavalcanti CT. Occlusal changes of Class II malocclusion treatment between Fränkel and the eruption guidance appliances. *Angle Orthod* 2004;74:521-525.
  27. Janson G, Nakamura A, Chiqueto K, Castro R, de Freitas MR, Henriques JF. Treatment stability with the eruption guidance appliance. *Am J Orthod Dentofacial Orthop* 2007;131:717-728.
  28. Janson G, Nakamura A, de Freitas MR, Henriques JF, Pinzan A. Apical root resorption comparison between Fränkel and eruption guidance appliances. *Am J Orthod Dentofacial Orthop* 2007;131:729-735.
  29. Janson GR, da Silva CC, Bergersen EO, Henriques JF, Pinzan A. Eruption Guidance Appliance effects in the treatment of Class II, Division 1 malocclusions. *Am J Orthod Dentofacial Orthop* 2000;117:119-129.
  30. Janson GR, Pereira AC, Bergersen EO, Henriques JF, Pinzan A, de Almeida RR. Cephalometric evaluation of the eruption guidance appliance in Class II, division 1 treatment. *J Clin Orthod* 1997;31:299-306.
  31. Myrlund R, Keski-Nisula K, Kerosuo H. Stability of orthodontic treatment outcomes after 1-year treatment with the eruption guidance appliance in the early mixed dentition: A follow-up study. *Angle Orthod* 2019;89:206-213.
  32. Ortho-Tain®. Ortho-Tain Class III™ Appliance.
  33. Collection AAOFCGL. Available at: [https://www.aaoflegacycollection.org/aaof\\_home.html](https://www.aaoflegacycollection.org/aaof_home.html).
  34. Dahlberg G. Statistical methods for medical and biological students. George Alien and Unwin, Ltd., London; 1940.
  35. Houston WJ. The analysis of errors in orthodontic measurements. *Am J Orthod* 1983;83:382-390.
  36. Bombonatti R, Castillo AAD, Bombonatti JFS, Garib D, Tompson B, Janson G. Cephalometric and occlusal changes of Class III malocclusion treated with or without extractions. *Dental Press J Orthod* 2020;25:24-32.
  37. Pithon MM. Importance of the control group in scientific research. *Dental Press J Orthod* 2013;18:13-14.
- 
-

38. Tollaro I, Baccetti T, Franchi L. Craniofacial changes induced by early functional treatment of Class III malocclusion. *Am J Orthod Dentofacial Orthop* 1996;109:310-318.
  39. Baccetti T, Franchi L, McNamara JA, Jr. Treatment and posttreatment craniofacial changes after rapid maxillary expansion and facemask therapy. *Am J Orthod Dentofacial Orthop* 2000;118:404-413.
  40. Yavuz I, Halicioğlu K, Ceylan I, Dağsuyu IM, Erdem A. The effects of face mask therapy with and without rapid maxillary expansion in adolescent patients. *Aust Orthod J* 2012;28:63-71.
  41. Zhang W, Qu HC, Yu M, Zhang Y. The Effects of Maxillary Protraction with or without Rapid Maxillary Expansion and Age Factors in Treating Class III Malocclusion: A Meta-Analysis. *PLoS One* 2015;10:e0130096.
  42. León-Salazar V, Janson G, de Freitas MR, de Almeida RR, León-Salazar R. Nonextraction treatment of a skeletal Class III malocclusion. *Am J Orthod Dentofacial Orthop* 2009;136:736-745.
- 
-

## FIGURE LEGENDS

**Fig. 1:** Class III Corrector Appliance.<sup>32</sup> A, front view; B, posterior front view; C, right side view; D, left side view; E, top view; F, bottom view.

**Fig. 2:** Pretreatment and posttreatment facial and intraoral photographs of a patient treated with the Class III Corrector Appliance (after 12 months of treatment).

**Fig. 3:** Cephalometric superimpositions of the initial and final mean tracings of the experimental group: black line, pretreatment; red line, posttreatment.

**Fig. 4:** Cephalometric superimpositions of the initial and final mean tracings of the control group: black line, pretreatment; red line, posttreatment.

---

---

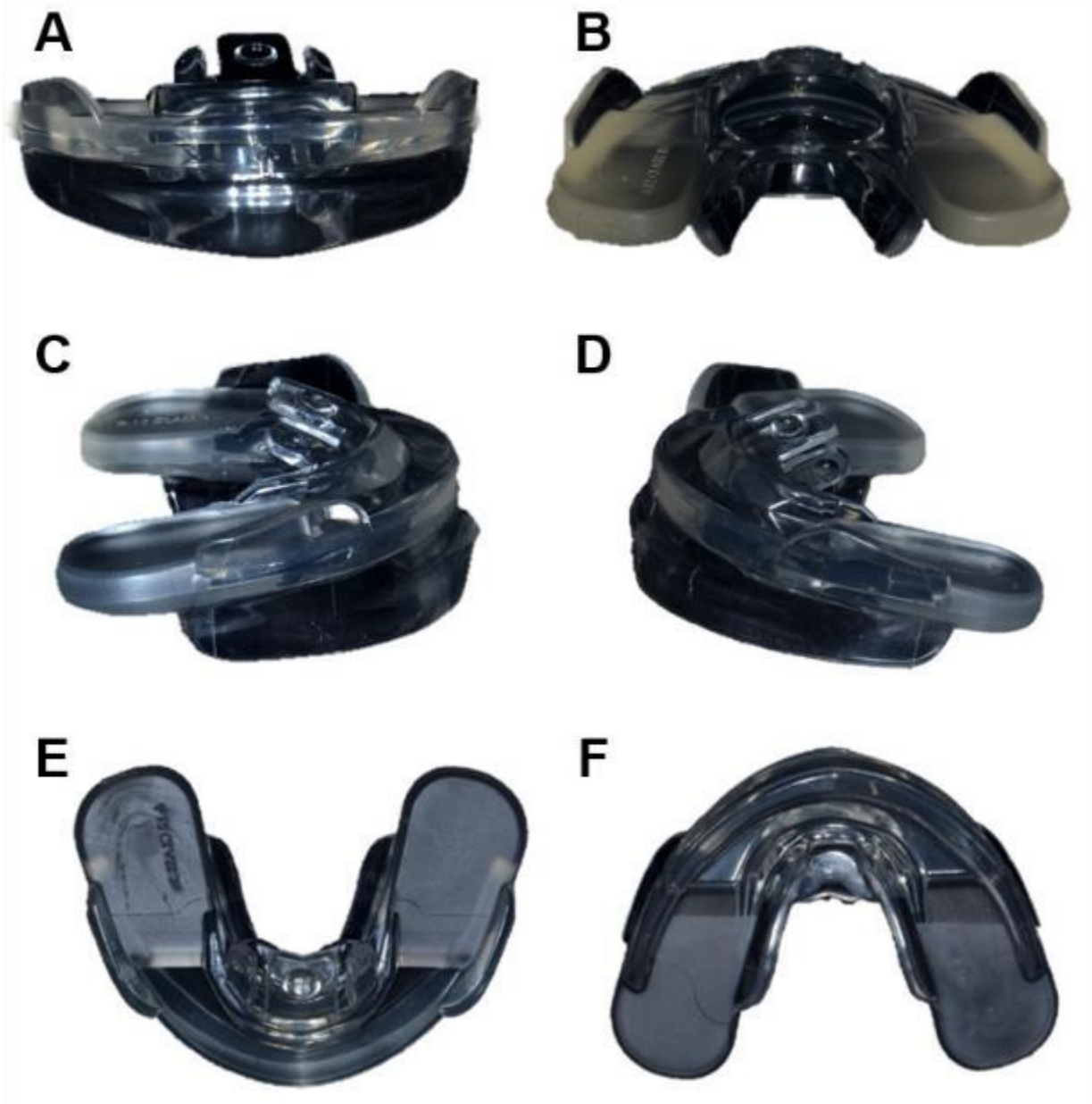


Fig. 1

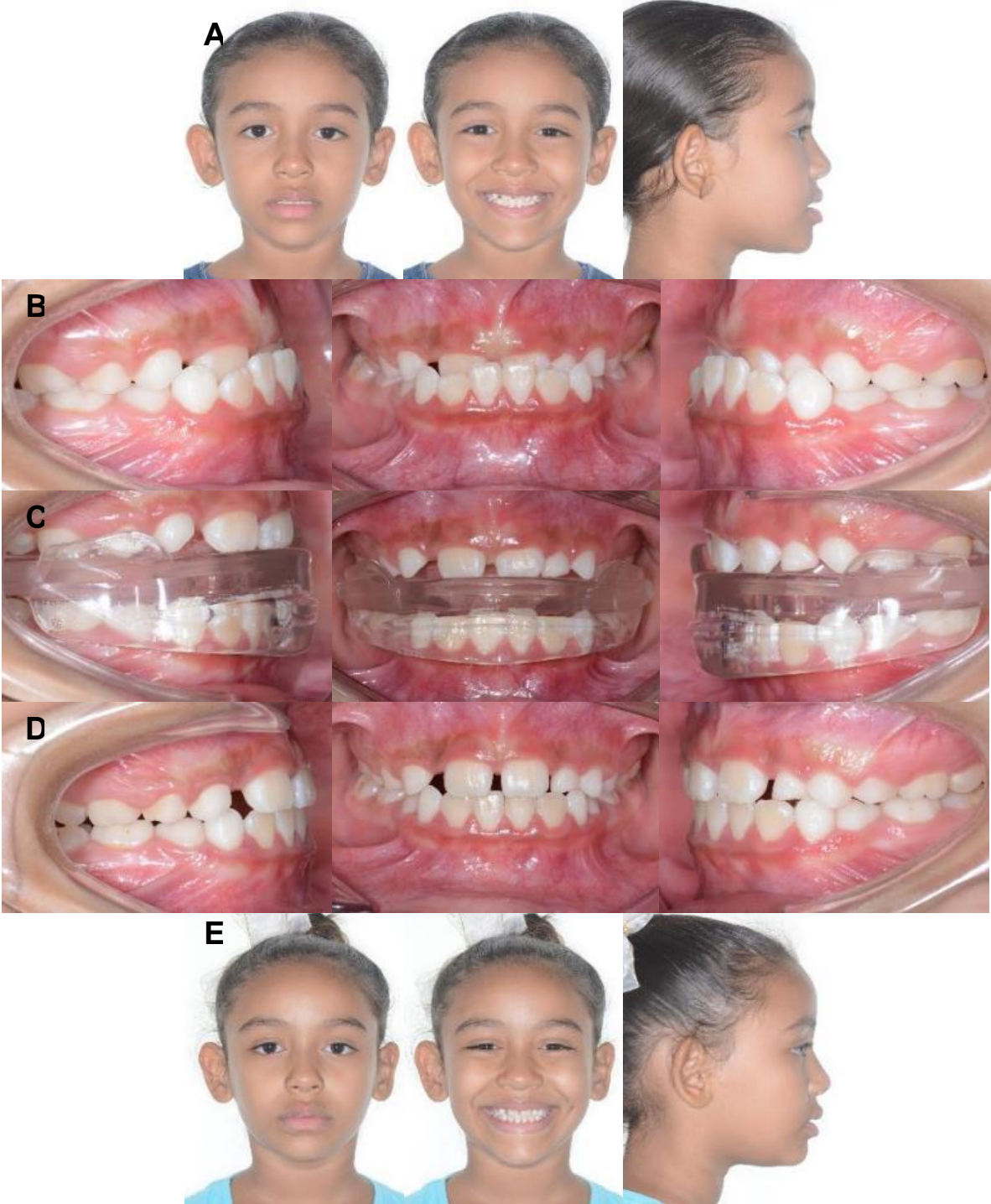


Fig. 2



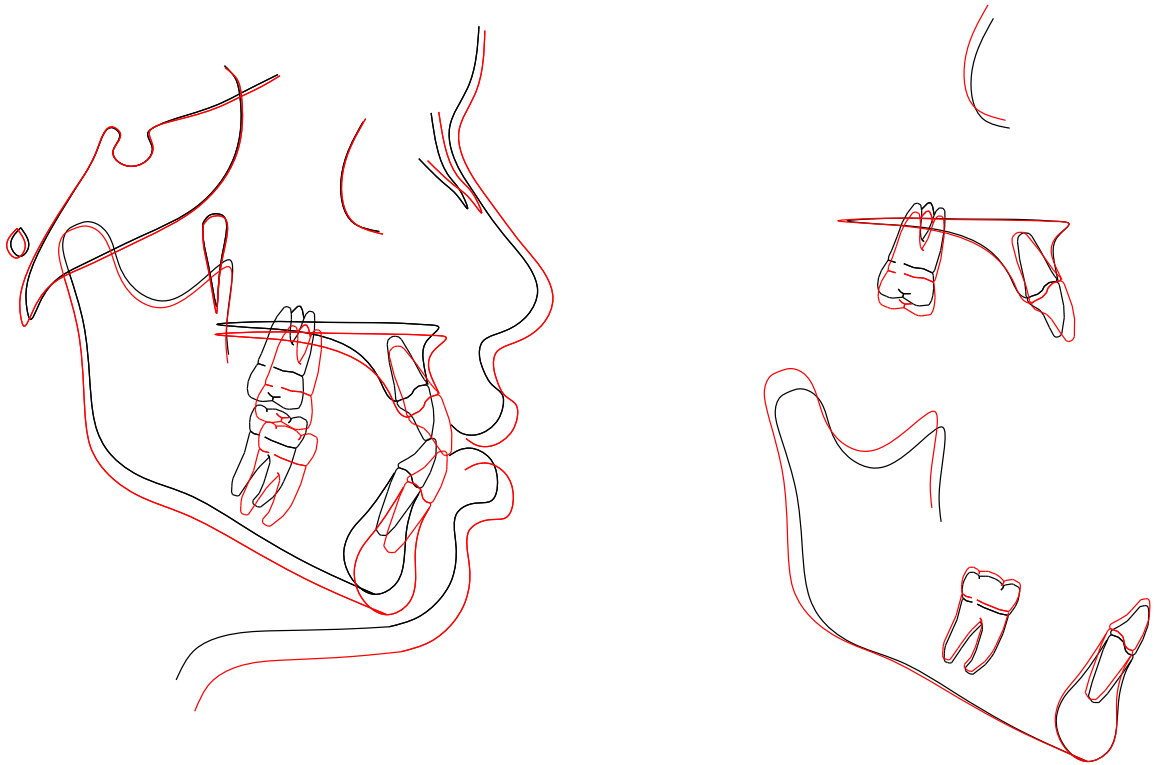


Fig. 3

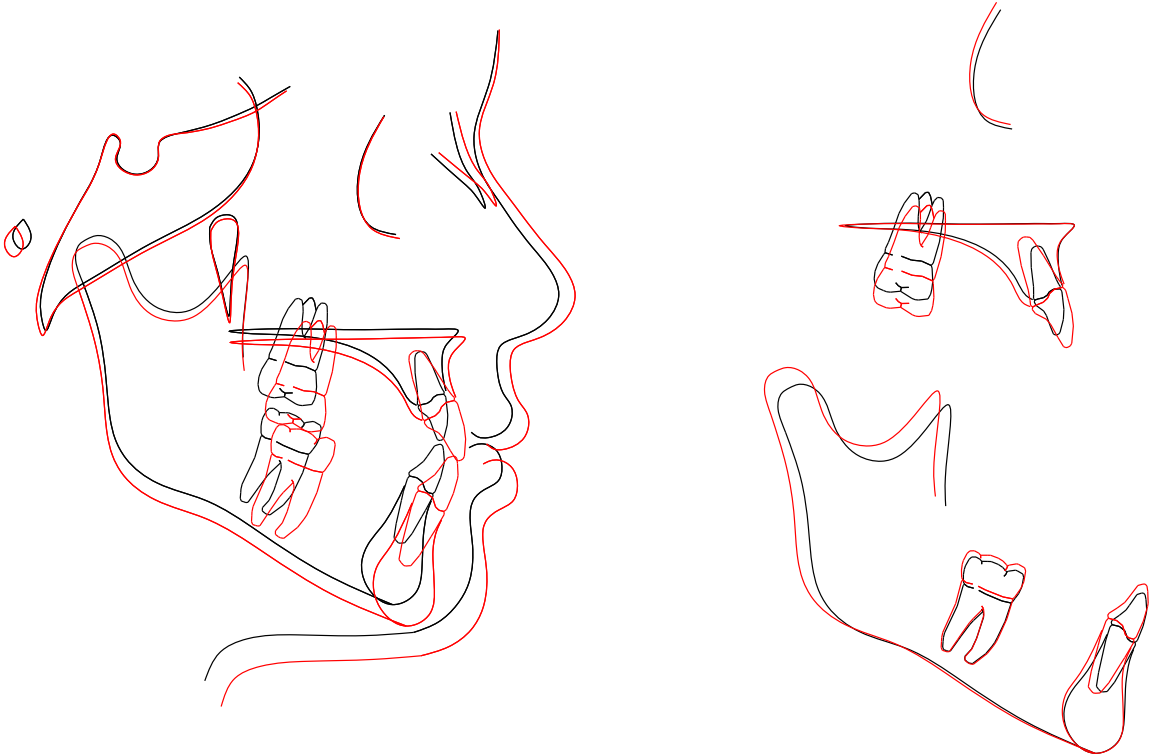


Fig. 4

**Table I:** Definitions of the cephalometric variables used.

VARIABLES	DEFINITION
<b>MAXILLARY SKELETAL COMPONENTS</b>	
SNA (°)	Angle formed by SN and NA planes.
Co-A (mm)	Condylion to A-point distance (effective maxillary length).
A-Nperp (mm)	Linear distance from A-point to nasion-perpendicular.
<b>MANDIBULAR SKELETAL COMPONENTS</b>	
SNB (°)	Angle formed by NA and NB planes.
Co-Gn (mm)	Condylion to Gnathion distance (effective mandibular length).
Pog-Nperp (mm)	Linear distance from pogonion to nasion-perpendicular.
<b>MAXILLOMANDIBULAR SAGITTAL RELATIONSHIP</b>	
ANB (°)	Angle formed by NA and NB planes.
Wits (mm)	Distance between perpendicular projections of points A and B on the functional occlusal plane.
NAP (°)	Angle between points N, A and P.
Mx/Md Difference (mm)	Difference of Co-Gn and Co-A.
<b>MAXILLOMANDIBULAR VERTICAL RELATIONSHIP</b>	
FMA (°)	Angle formed by FH plane and MP.
SN.GoGn (°)	Angle formed by SN and GoGn planes.
SN.OccPlane (°)	SN to occlusal plane angle.
LAFH (mm)	Distance between ANS point and Me point.
<b>MAXILLARY DENTOALVEOLAR COMPONENTS</b>	
Mx1.NA (°)	Angle between maxillary incisor long axis and NA plane.
Mx1-NA (mm)	Distance from maxillary incisor edge to NA plane.
Mx1-PP (mm)	Perpendicular distance between incisal edge of maxillary incisor and palatal plane.
Mx6-PP (mm)	Perpendicular distance between the mesiobuccal cusp of the maxillary first molar and the palatal plane.
Mx6-Ptv (mm)	Distance between the mesiobuccal cusp of the maxillary first molar and the pterygoid vertical.
<b>MANDIBULAR DENTOALVEOLAR COMPONENTS</b>	
Md1.NB (°)	Angle between mandibular incisor long axis and NB plane.
Md1-NB (mm)	Distance from mandibular incisor edge to NB plane.
Md1-MP (mm)	Perpendicular distance between the incisal edge of the mandibular central incisor and the mandibular plane.
IMPA (°)	Formed by the intersection of the long axis of the mandibular incisor and mandibular plane.
Md6-MP (mm)	Perpendicular distance between the mesiobuccal cusp of the mandibular first molar and the mandibular plane.
Md6-Ptv (mm)	Distance between the mesiobuccal cusp of the mandibular first molar and the pterygoid vertical.
<b>DENTOALVEOLAR RELATIONSHIP</b>	
Overjet (mm)	Distance between the incisal edge of maxillary and mandibular central incisor, parallel to the occlusal plane.
Overbite (mm)	Distance between the incisal edge of maxillary and mandibular central incisor, perpendicular to the occlusal plane.
Molar Relationship (mm)	Distance between mesial points of maxillary and mandibular molars, parallel to Frankfort plane.
<b>SOFT TISSUE PROFILE</b>	
NLA (°)	Angle formed by the intersection of the line Prn and Sn points and the line that passes through the Sn and Ls points.
UL – Sline (mm)	Perpendicular distance between S Line and UL (most anterior point of upper lip).
LL – Sline (mm)	Perpendicular distance between S Line and LL (most anterior point of lower lip).
G'.Sn.Pog' (°)	Angle formed between soft-tissue glabella, subnasal and pogonion (facial convexity).

**Table II:** Intergroup comparison of initial and final ages, period of evaluation, sex and anterior teeth relationships distribution.

Variable	Experimental Group (n=22)		Control Group (n=22)		P	
	Mean	SD	Mean	SD		
	<b>Initial Age (y)</b>	7.63	0.96	7.21		0.60
<b>Final Age (y)</b>	9.38	1.01	9.12	0.90	0.369†	
<b>Period of evaluation (y)</b>	1.72	0.48	1.87	0.60	0.453‡	
<b>Sex</b>	<b>n</b>	<b>%</b>	<b>n</b>	<b>%</b>		
<b>Female</b>	10	45.5	10	45.5	1.000‡	
<b>Male</b>	12	54.5	12	54.5		
<b>Initial</b>		<b>n</b>	<b>%</b>	<b>n</b>	<b>%</b>	0.008*
	<b>ACB</b>	16	72.73	8	36.36	
	<b>Edge-to-edge</b>	6	27.27	7	31.82	
	<b>Normal overjet</b>	0	0.00	7	31.82	

† T-test

‡ Chi-square test

‡ Mann-Whitney U test

\* Statistically significant at  $P < 0.05$

Table III: Intergroup comparison of the initial cephalometric characteristics.

Variable	Experimental Group T1 (n=22)		Control Group T1 (n=22)		Mean Difference (T2-T1)	95% CI		P
	Mean	SD	Mean	SD				
<b>MAXILLARY SKELETAL COMPONENTS</b>								
SNA (°)	81.25	4.09	80.31	4.16	-0.94	-1.57	3.45	0.453†
Co-A (mm)	73.68	2.86	76.46	4.85	2.77	-5.20	-0.35	0.018‡*
A-Nperp (mm)	-1.16	2.32	0.56	4.20	1.72	-3.79	0.34	0.038‡*
<b>MANDIBULAR SKELETAL COMPONENTS</b>								
SNB (°)	80.05	4.04	78.74	3.48	-1.31	-0.98	3.61	0.254†
Co-Gn (mm)	96.86	5.39	99.12	5.04	2.27	-5.44	0.91	0.157†
Pog-Nperp (mm)	-4.50	4.43	-1.53	6.11	2.97	-6.22	0.27	0.072†
<b>MAXILLOMANDIBULAR SAGITTAL RELATIONSHIP</b>								
ANB (°)	1.20	1.51	1.56	2.51	0.36	-1.62	0.90	0.563†
Wits (mm)	-5.94	3.31	-7.43	4.87	-1.49	-1.04	4.03	0.245‡
NAP (°)	3.40	4.55	-3.31	6.56	0.09	-3.52	3.35	0.960†
Mx/Md Diff. (mm)	23.17	3.07	22.67	3.31	-0.50	-1.44	2.45	0.603†
<b>MAXILLOMANDIBULAR VERTICAL RELATIONSHIP</b>								
FMA (°)	27.95	4.53	25.68	3.57	-2.27	-0.21	4.76	0.072†
SN.GoGn (°)	31.80	5.24	32.19	4.36	0.40	-3.33	2.54	0.787†
SN.OP (°)	18.25	5.09	20.08	3.84	1.83	-4.58	0.91	0.185†
LAFH (mm)	55.99	3.21	58.14	4.22	2.15	-4.43	0.13	0.064†
<b>MAXILLARY DENTOALVEOLAR COMPONENTS</b>								
Mx1.NA (°)	19.90	8.69	15.60	7.82	-4.30	-0.73	9.33	0.092†
MX1-NA (mm)	1.55	2.18	0.79	2.25	-0.77	-0.58	2.12	0.257†
Mx1-PP (mm)	23.06	1.81	23.16	2.25	0.10	-1.34	1.15	0.878†
Mx6-PP (mm)	16.38	2.24	14.58	3.10	-1.80	0.16	3.45	0.032‡*
Mx6-Ptv (mm)	15.30	2.35	17.96	3.40	2.66	-4.44	-0.88	0.004‡*
<b>MANDIBULAR DENTOALVEOLAR COMPONENTS</b>								
Md1.NB (°)	26.40	5.52	20.56	6.34	-5.84	2.22	9.45	0.002‡*
Md1-NB (mm)	4.26	1.75	2.52	1.92	-1.74	0.62	2.85	0.003‡*
Md1-MP (mm)	33.65	1.98	33.81	3.13	0.17	-1.76	1.43	0.832†
IMPA (°)	90.87	5.40	85.84	7.05	-5.03	1.20	8.85	0.011‡*
Md6-MP (mm)	23.90	1.78	24.47	2.40	0.57	-1.86	0.71	0.373†
Md6-Ptv (mm)	9.87	2.27	12.08	3.47	2.20	-3.99	-0.42	0.006‡*
<b>DENTOALVEOLAR RELATIONSHIP</b>								
Overbite (mm)	0.59	1.53	-0.33	1.56	-0.92	-0.02	1.87	0.041‡*
Overjet (mm)	-1.20	1.49	0.08	1.94	1.29	-2.34	-0.24	0.018‡*
Molar Relationship (mm)	-1.80	1.31	-2.15	1.58	-0.35	-0.53	1.23	0.418‡
<b>SOFT TISSUE PROFILE</b>								
NLA (°)	100.57	12.14	107.69	10.60	7.12	-14.05	-0.19	0.044‡*
UL-SLine (mm)	1.93	2.04	0.46	2.00	-1.47	0.24	2.70	0.020‡*
LL-SLine (mm)	4.35	2.15	1.46	1.82	-2.89	1.68	4.10	0.001‡*
G.Sn.Pg' (°)	172.41	4.54	171.86	5.94	-0.55	-2.67	3.77	0.8330‡

† T-test

‡ Mann-Whitney U Test

\* Statistically significant at  $P < 0.05$

**Table IV:** Intragroup treatment changes of the experimental group.

Variable	T1		T2		Mean Difference (T2-T1)	95% CI		P
	Mean	SD	Mean	SD				
<b>MAXILLARY SKELETAL COMPONENTS</b>								
SNA (°)	81.25	4.09	81.19	4.38	-0.06	-0.57	0.69	0.847†
Co-A (mm)	73.68	2.86	76.01	2.82	2.33	-2.95	-1.71	<0.001†*
A-Nperp (mm)	-1.16	2.32	-1.08	2.75	0.08	-0.64	0.47	0.762†
<b>MANDIBULAR SKELETAL COMPONENTS</b>								
SNB (°)	80.05	4.04	80.57	4.77	0.52	-1.19	0.15	0.119†
Co-Gn (mm)	96.86	5.39	101.34	5.14	4.48	-5.49	-3.47	<0.001†*
Pog-Nperp (mm)	-4.51	4.43	-3.11	5.13	1.40	-2.57	-0.22	0.022†*
<b>MAXILLOMANDIBULAR SAGITTAL RELATIONSHIP</b>								
ANB (°)	1.20	1.51	0.62	1.57	-0.58	0.13	1.03	0.004‡*
Wits (mm)	-5.94	3.31	-4.85	2.09	1.10	-2.80	0.61	0.363‡
NAP (°)	-3.40	4.55	-1.55	4.60	1.85	-2.89	-0.81	0.001†*
Mx/Md Diff. (mm)	22.67	3.31	25.49	4.48	2.82	-4.02	-1.62	<0.001†*
<b>MAXILLOMANDIBULAR VERTICAL RELATIONSHIP</b>								
FMA (°)	27.95	4.53	26.87	4.50	-1.08	0.17	1.99	0.022†*
SN.GoGn (°)	31.80	5.24	31.07	6.17	-0.72	-0.16	1.60	0.103†
SN.OP (°)	18.25	5.09	15.63	5.08	-2.62	1.62	3.62	<0.001†*
LAFH (mm)	55.99	3.21	57.78	3.34	1.79	-2.32	-1.25	<0.001†*
<b>MAXILLARY DENTOALVEOLAR COMPONENTS</b>								
Mx1.NA (°)	19.90	8.69	28.45	5.28	8.56	-11.80	-5.31	<0.001†*
MX1-NA (mm)	1.56	2.18	4.57	1.67	3.01	-3.64	-2.39	<0.001†*
Mx1-PP (mm)	23.06	1.81	23.79	2.07	0.73	-1.34	-0.12	0.021†*
Mx6-PP (mm)	16.38	2.24	18.47	1.75	2.09	-3.04	-1.14	<0.001‡*
Mx6-Ptv (mm)	15.31	2.36	17.14	2.37	1.83	-2.43	-1.24	<0.001†*
<b>MANDIBULAR DENTOALVEOLAR COMPONENTS</b>								
Md1.NB (°)	26.40	5.52	26.96	5.63	0.56	-1.76	0.65	0.154‡
Md1-NB (mm)	4.26	1.75	4.76	2.03	0.50	-0.92	-0.07	0.023†*
Md1-MP (mm)	33.65	1.98	35.06	1.86	1.41	-1.77	-1.06	<0.001†*
IMPA (°)	90.87	5.40	91.84	5.38	0.97	-2.10	0.17	0.009‡*
Md6-MP (mm)	23.90	1.78	24.71	1.86	0.81	-1.20	-0.42	<0.001†*
Md6-Ptv (mm)	9.87	2.27	11.91	2.67	2.04	-2.77	-1.31	<0.001†*
<b>DENTOALVEOLAR RELATIONSHIP</b>								
Overbite (mm)	0.59	1.53	0.58	1.12	-0.01	-0.60	0.63	0.963†
Overjet (mm)	-1.21	1.49	0.66	1.73	1.86	-2.65	-1.07	<0.001†*
Molar Relationship (mm)	-1.80	1.31	-1.61	1.50	0.20	-0.78	0.39	0.903‡
<b>SOFT TISSUE PROFILE</b>								
NLA (°)	100.57	12.14	100.48	10.83	-0.09	-2.18	2.36	0.938†
UL-SLine (mm)	1.78	1.93	1.93	2.04	0.15	-0.50	0.21	0.405†
LL-SLine (mm)	4.36	2.15	4.63	2.49	0.28	-0.63	0.08	0.121†
G.Sn.Pg' (°)	172.41	4.54	171.49	4.48	-0.92	0.01	1.83	0.048†*

† Paired t-test

‡ Wilcoxon Test

\* Statistically significant at  $P < 0.05$

**Table V:** Intragroup normal growth changes of the control group.

Variable	T1		T2		Mean Difference (T2-T1)	95% CI	P	
	Mean	SD	Mean	SD				
<b>MAXILLARY SKELETAL COMPONENTS</b>								
SNA (°)	80.31	4.16	80.24	4.09	-0.07	-0.66	0.81	0.838†
Co-A (mm)	76.46	4.85	77.94	5.08	1.48	-2.52	-0.44	0.007†*
A-Nperp (mm)	0.56	4.20	1.01	3.72	0.45	-0.42	1.53	0.246†
<b>MANDIBULAR SKELETAL COMPONENTS</b>								
SNB (°)	78.74	3.48	78.99	3.00	0.25	-1.04	0.53	0.508†
Co-Gn (mm)	99.12	5.04	103.43	5.76	4.30	-5.53	-3.08	<0.001†*
Pog-Nperp (mm)	-1.53	6.11	-1.53	6.08	0.01	-1.62	1.61	0.995†
<b>MAXILLOMANDIBULAR SAGITTAL RELATIONSHIP</b>								
ANB (°)	1.56	2.51	1.24	2.74	-0.33	-0.20	0.85	0.209†
Wits (mm)	-7.43	4.87	-5.45	4.32	1.98	-3.90	-0.07	0.011‡*
NAP (°)	1.56	2.50	1.23	2.73	-0.33	-0.198	0.253	0.209†
Mx/Md Diff. (mm)	22.67	3.31	25.49	4.48	2.82	-4.02	-1.62	<0.001†*
<b>MAXILLOMANDIBULAR VERTICAL RELATIONSHIP</b>								
FMA (°)	25.68	3.57	26.37	4.25	0.69	-1.67	0.29	0.156†
SN.GoGn (°)	32.19	4.36	32.52	4.99	0.33	-1.34	0.68	0.501†
SN.OP (°)	20.08	3.84	18.30	4.67	-1.78	0.30	3.27	0.023‡*
LAFH (mm)	58.14	4.22	60.94	5.06	2.80	-3.69	-1.91	<0.001†*
<b>MAXILLARY DENTOALVEOLAR COMPONENTS</b>								
Mx1.NA (°)	15.60	7.82	24.59	4.84	9.00	-12.43	-5.56	<0.001†*
MX1-NA (mm)	0.79	2.25	3.11	1.54	2.32	-3.24	-1.39	<0.001†*
Mx1-PP (mm)	23.16	2.25	25.27	2.57	2.12	-3.13	-1.11	<0.001†*
Mx6-PP (mm)	14.58	3.10	17.72	2.21	3.15	-4.38	-1.91	<0.001†*
Mx6-Ptv (mm)	17.96	3.40	19.04	3.01	1.07	-1.70	-0.45	0.002†*
<b>MANDIBULAR DENTOALVEOLAR COMPONENTS</b>								
Md1.NB (°)	20.56	6.34	22.00	5.33	1.43	-2.77	-0.09	0.037†*
Md1-NB (mm)	2.52	1.92	3.42	1.87	0.90	-1.36	-0.44	<0.001†*
Md1-MP (mm)	33.81	3.13	35.66	3.41	1.85	-2.31	-1.39	<0.001†*
IMPA (°)	85.84	7.05	86.79	6.43	0.95	-2.41	0.52	0.194†
Md6-MP (mm)	24.47	2.40	25.75	2.16	1.28	1.86	-0.70	<0.001†*
Md6-Ptv (mm)	12.08	3.47	13.56	3.61	1.49	-2.39	-0.58	0.003†*
<b>DENTOALVEOLAR RELATIONSHIP</b>								
Overbite (mm)	-0.33	1.56	0.62	1.88	0.96	-1.97	0.06	0.064†
Overjet (mm)	0.08	1.94	1.36	1.82	1.27	-2.25	-0.30	0.013†*
Molar Relationship (mm)	-2.15	1.58	-2.19	1.90	-0.04	-0.55	0.63	0.887†
<b>SOFT TISSUE PROFILE</b>								
NLA (°)	107.69	10.60	107.56	13.43	-0.13	-4.94	5.20	0.581‡
UL-SLine (mm)	0.46	2.00	0.51	1.89	0.06	-0.98	0.87	0.904†
LL-SLine (mm)	1.46	1.82	1.56	2.03	0.09	-0.96	0.78	0.830†
G.Sn.Pg' (°)	171.86	5.94	170.36	6.00	-1.50	0.50	2.50	0.005†*

† Paired t-test

‡ Wilcoxon Test

\* Statistically significant at  $P<0.05$

**Table VI:** Intergroup comparison between treatment changes and normal growth.

Variable	Experimental Group		Control Group		Mean Difference (T2-T1)	95% CI		P
	T2-T1		T2-T1					
	Mean	SD	Mean	SD				
<b>MAXILLARY SKELETAL COMPONENTS</b>								
SNA (°)	-0.06	1.42	-0.07	1.00	-0.01	-0.92	0.95	0.977†
Co-A (mm)	2.33	1.40	1.48	2.34	-0.85	-0.32	2.02	0.151†
A-Nperp (mm)	0.08	1.25	-0.56	2.00	-0.64	-0.45	1.73	0.155†
<b>MANDIBULAR SKELETAL COMPONENTS</b>								
SNB (°)	0.52	1.51	0.26	1.77	-0.27	-0.73	1.27	0.592†
Co-Gn (mm)	4.48	2.28	4.31	2.76	-0.18	-1.36	1.72	0.817†
Pog-Nperp (mm)	1.40	2.64	0.00	3.64	-1.39	-0.55	3.33	0.154†
<b>MAXILLOMANDIBULAR SAGITTAL RELATIONSHIP</b>								
ANB (°)	-0.58	1.01	-0.33	1.19	0.25	-0.92	0.42	0.46†
Wits (mm)	1.10	3.85	1.98	4.32	0.89	-3.37	1.60	0.159‡
NAP (°)	1.85	2.34	1.36	2.80	-0.50	-1.07	2.07	0.528†
Mx/Md Diff. (mm)	2.15	1.57	2.82	2.71	0.67	-2.02	0.67	0.319†
<b>MAXILLOMANDIBULAR VERTICAL RELATIONSHIP</b>								
FMA (°)	-1.08	2.05	0.69	2.20	1.77	-3.07	-0.48	0.008†*
SN.GoGn (°)	-0.72	1.99	0.33	2.27	1.06	-2.35	0.24	0.109†
SN.OP (°)	-2.62	2.26	-1.78	3.35	0.84	-2.57	0.90	0.337†
LAFH (mm)	1.79	1.21	2.80	2.00	1.01	-2.02	-0.01	0.048†*
<b>MAXILLARY DENTOALVEOLAR COMPONENTS</b>								
Mx1.NA (°)	8.56	7.31	9.00	7.75	0.44	-5.03	4.15	0.847†
MX1-NA (mm)	3.01	1.40	2.32	2.09	-0.70	-0.39	1.78	0.202†
Mx1-PP (mm)	0.73	1.38	2.12	2.28	1.39	-2.53	-0.24	0.059‡
Mx6-PP (mm)	2.09	2.14	3.15	2.79	1.06	-2.57	0.45	0.047‡*
Mx6-Ptv (mm)	1.83	1.35	1.07	1.41	-0.76	-0.08	1.60	0.075†
<b>MANDIBULAR DENTOALVEOLAR COMPONENTS</b>								
Md1.NB (°)	0.56	2.71	1.43	3.02	0.88	-2.62	0.87	0.316†
Md1-NB (mm)	0.50	0.95	0.90	1.03	0.41	-1.01	0.20	0.183†
Md1-MP (mm)	1.41	0.81	1.85	1.04	0.43	-1.00	0.13	0.131†
IMPA (°)	0.97	2.56	0.95	3.30	-0.02	-1.78	1.82	0.888‡
Md6-MP (mm)	0.81	0.89	1.28	1.31	0.47	-1.15	0.21	0.171†
Md6-Ptv (mm)	2.04	1.64	1.49	2.05	-0.56	-0.57	1.68	0.327†
<b>DENTOALVEOLAR RELATIONSHIP</b>								
Overbite (mm)	-0.01	1.38	0.96	2.29	0.97	-2.12	0.18	0.078‡
Overjet (mm)	1.86	1.78	1.27	2.19	-0.59	-0.63	1.80	0.335†
Molar Relationship (mm)	0.20	1.32	-0.04	1.34	-0.24	-0.57	1.04	0.558†
<b>SOFT TISSUE PROFILE</b>								
NLA (°)	-0.09	5.12	-0.13	11.44	-0.05	-5.34	5.44	0.432‡
UL-SLine (mm)	-0.15	0.80	0.05	2.09	0.20	-1.16	0.76	0.425‡
LL-SLine (mm)	0.28	0.81	0.09	1.96	-0.19	-0.73	1.10	0.814‡
G.Sn.Pg' (°)	-0.92	2.05	-1.50	2.26	-0.58	-0.73	1.89	0.376†

† T-test

‡ Mann-Whitney U Test

\* Statistically significant at  $P < 0.05$



**Table VII:** Intragroup and intergroup comparisons of the proportions of Anterior Crossbite (ACB), Edge-to-Edge and normal overjet at T1 and T2 (McNemar and Chi-square tests).

	Variable	Experimental Group		Control Group		P-value Chi-Square tests
		(n=22)		(n=22)		
		n	%	n	%	
Initial	ACB	16	72.73	8	36.36	0.008*
	Edge-to-edge	6	27.27	7	31.82	
	Normal overjet	0	0.00	7	31.82	
Final	ACB	4	18.18	4	18.18	0.942
	Edge-to-edge	6	27.27	7	31.82	
	Normal overjet	12	54.55	11	50	
<b>P-value McNemar tests ‡</b>		0.007*		0.346		

\* Statistically significant at  $P < 0.05$

‡ The ACB and Edge-to-edge patients were grouped as 'Non-normal' to allow a 2x2 table comparison.

# **3 DISCUSSION**

---



### 3 DISCUSSION

The groups were similar regarding the initial and final ages, period of evaluation, and sex distribution. But, despite all efforts, the experimental group had a significantly greater number of patients with anterior crossbite at pretreatment, and among 32 variables, there were significant differences among 13 cephalometric variables.

Most of the treatment changes were similar to normal growth changes. There were significant increases in maxillary and mandibular effective lengths and in the maxillomandibular differential, therefore increasing the skeletal Class III discrepancy. This was also discretely shown by the ANB. Therefore, it seems that the appliance did not have a skeletal effect in the skeletal Class III relationship. These effects are similar to the Frankel FRIII appliance in Class III malocclusion correction.(YANG; LI; BAI; SU *et al.*, 2014) Usually, Class III removable functional appliances have limited effects in correction of skeletal Class III discrepancies.(TOLLARO; BACCETTI; FRANCHI, 1996) Maxillary expansion followed by face masks usually present a skeletal effect in Class III malocclusion correction at a similar age range.(BACCETTI; FRANCHI; MCNAMARA, 2000; YAVUZ; HALICIOĞLU; CEYLAN; DAĞSUYU *et al.*, 2012; ZHANG; QU; YU; ZHANG, 2015) However, the forces applied are delivered by elastics and are considered to be in the orthopedic range.(LEÓN-SALAZAR; JANSON; DE FREITAS; DE ALMEIDA *et al.*, 2009) Additionally, face masks are extraoral appliances and are very unattractive.(YAVUZ; HALICIOĞLU; CEYLAN; DAĞSUYU *et al.*, 2012; ZHANG; QU; YU; ZHANG, 2015)

The major effects of the appliance were in the vertical relationships. It was able to produce a decrease in the mandibular plane angle, which was significantly different from normal growth, increasing this angle. Additionally, it also significantly restricted the increase of the lower anterior face height. These effects may be consequent to the occlusal shelves of the appliance that can cause some restriction in vertical development of the posterior teeth.(JANSON; DA SILVA; BERGERSEN; HENRIQUES *et al.*, 2000) This was clearly shown by the significantly smaller vertical development of the maxillary first molars. This effect is opposite to the effects of the Frankel FRIII and to the face mask that usually tend to increase the mandibular plane

---

angle and the lower anterior face height, causing a clockwise mandibular rotation.(WOON; THIRUVENKATACHARI, 2017; YANG, 1996) Therefore, it is mostly useful in patients with a vertical growth pattern.

The appliance did have an effect in correcting the anterior crossbite by labially tipping and protruding the maxillary incisors. Nevertheless, these changes were not significantly greater than normal growth. This is probably because the maxillary deciduous incisors are more vertically positioned than the maxillary permanent incisors. Consequently, as the permanent maxillary incisors erupt, they already do it, with a greater labial inclination than their former deciduous incisors. Therefore, no significant intergroup differences were observed. Similar effects were observed for the Frankel FRIII appliance.(YANG, 1996) On the other hand, the face mask is able to significantly labially tip and protrude the maxillary incisors, beyond the capability of normal growth.(WOON; THIRUVENKATACHARI, 2017)

Changes in the mandibular incisors consisted in labial tipping, protrusion and vertical development, and in the mandibular molars, they consisted in vertical development and mesialization, which were all similar to normal growth. Therefore, the appliance appears to have had no significant effects in the mandibular dentoalveolar components.

The significant intragroup changes in the maxillary incisors of the treated group contributed to the significant improvement of the overjet in the group. Nevertheless, consequent to the similar changes in the foreseen cephalometric variables, there were no significant intergroup differences in overbite, overjet and molar relationship. Effects of the Frankel FRIII are similar to these effects.(YANG, 1996) On the other hand, the facemask demonstrated significant improvement in overjet and molar relationship, when compared to normal growth changes.(WOON; THIRUVENKATACHARI, 2017) Likewise, a similar interpretation applies to the soft tissue profile variables.

Despite there were only small treatment changes in the intergroup comparisons in the cephalometric variables, the amount of patients with anterior crossbite in the treated group decreased significantly between the pre- and posttreatment stages in the treated group, while it did not happen in the control group. Additionally, while the percentage of patients in the treated groups was significantly greater in the initial stage, than in the control group, it became similar in the posttreatment stage. There

---

---

was improvement of anterior crossbite in 12 of the 16 patients (75%) that originally had a complete anterior crossbite and there was correction of anterior cross-bite or edge to edge anterior occlusion in 12 of the original 22 patients (54.54%) that presented these problems. This demonstrates the efficiency of the appliance in correcting the anterior crossbite.

Although the cephalometric results demonstrated minimum effects of this appliance, evaluation of anterior crossbite correction demonstrated very satisfactory results of the appliance effects. Because it is an intraoral appliance and very esthetic it can be a very important alternative for early Class III malocclusion treatment.

Treatment of some of these patients was somewhat compromised by the Covid-19 pandemic. In March 2020, 12 patients (55%) had already finished treatment. However, 10 were still under treatment and could not be monthly followed due to lockdown of the Dental School Clinics. They were remotely monitored by the student in charge of this investigation. In October 2020, when some clinical investigations, that were in their final stage, were allowed to return, the patients were recalled to continue treatment and have their final records taken. This may have had some impact in the results.



# **4 CONCLUSIONS**

---

---





## **4 CONCLUSIONS**

The pre-fabricated corrector appliance produced counter-clockwise rotation of the mandibular plane, smaller lower anterior face height increase and maxillary molar vertical development; improvement of anterior cross-bite in 75% of the patients; correction of anterior cross-bite or edge to edge anterior occlusion in 54.54% of the patients; and is an important alternative for early Class III malocclusion treatment.



# REFERENCES

---

---



## REFERENCES

AL-MOZANY, S. A.; DALCI, O.; ALMUZIAN, M.; GONZALEZ, C. *et al.* A novel method for treatment of Class III malocclusion in growing patients. **Prog Orthod**, 18, n. 1, p. 40, Dec 11 2017.

BACCETTI, T.; FRANCHI, L.; MCNAMARA, J. A., Jr. Treatment and posttreatment craniofacial changes after rapid maxillary expansion and facemask therapy. **Am J Orthod Dentofacial Orthop**, 118, n. 4, p. 404-413, Oct 2000.

BERGERSEN, E. O. The eruption guidance myofunctional appliances: how it works, how to use it. **Funct Orthod**, 1, n. 3, p. 28-29, 31-25, Sep-Oct 1984.

BORRIE, F.; BEARN, D. Early correction of anterior crossbites: a systematic review. **J Orthod**, 38, n. 3, p. 175-184, Sep 2011.

CHA, K. S. Skeletal changes of maxillary protraction in patients exhibiting skeletal class III malocclusion: a comparison of three skeletal maturation groups. **Angle Orthod**, 73, n. 1, p. 26-35, Feb 2003.

JANSON, G. R.; DA SILVA, C. C.; BERGERSEN, E. O.; HENRIQUES, J. F. *et al.* Eruption Guidance Appliance effects in the treatment of Class II, Division 1 malocclusions. **Am J Orthod Dentofacial Orthop**, 117, n. 2, p. 119-129, Feb 2000.

JANSON, G.; NAKAMURA, A.; CHIQUETO, K.; CASTRO, R. *et al.* Treatment stability with the eruption guidance appliance. **Am J Orthod Dentofacial Orthop**, 131, n. 6, p. 717-728, Jun 2007.

KESKI-NISULA, K.; LEHTO, R.; LUSA, V.; KESKI-NISULA, L. *et al.* Occurrence of malocclusion and need of orthodontic treatment in early mixed dentition. **Am J Orthod Dentofacial Orthop**, 124, n. 6, p. 631-638, Dec 2003.

LEÓN-SALAZAR, V.; JANSON, G.; DE FREITAS, M. R.; DE ALMEIDA, R. R. *et al.* Nonextraction treatment of a skeletal Class III malocclusion. **Am J Orthod Dentofacial Orthop**, 136, n. 5, p. 736-745, Nov 2009.

LI, C.; CAI, Y.; CHEN, S.; CHEN, F. Classification and characterization of class III malocclusion in Chinese individuals. **Head Face Med**, 12, n. 1, p. 31, Nov 7 2016.

---

---

MANDALL, N.; DIBIASE, A.; LITTLEWOOD, S.; NUTE, S. *et al.* Is early Class III protraction facemask treatment effective? A multicentre, randomized, controlled trial: 15-month follow-up. **J Orthod**, 37, n. 3, p. 149-161, Sep 2010.

MARTINA, R.; D'ANTÒ, V.; DE SIMONE, V.; GALEOTTI, A. *et al.* Cephalometric outcomes of a new orthopaedic appliance for Class III malocclusion treatment. **Eur J Orthod**, 42, n. 2, p. 187-192, Apr 1 2020.

MOON, Y. M.; AHN, S. J.; CHANG, Y. I. Cephalometric predictors of long-term stability in the early treatment of Class III malocclusion. **Angle Orthod**, 75, n. 5, p. 747-753, Sep 2005.

MYRLUND, R.; KESKI-NISULA, K.; KEROSUO, H. Stability of orthodontic treatment outcomes after 1-year treatment with the eruption guidance appliance in the early mixed dentition: A follow-up study. **Angle Orthod**, 89, n. 2, p. 206-213, Mar 2019.

OLTRAMARI-NAVARRO, P. V.; DE ALMEIDA, R. R.; CONTI, A. C.; NAVARRO RDE, L. *et al.* Early treatment protocol for skeletal Class III malocclusion. **Braz Dent J**, 24, n. 2, p. 167-173, 2013.

PELLEGRINO, M.; CARUSO, S.; CANTILE, T.; PELLEGRINO, G. *et al.* Early Treatment of Anterior Crossbite with Eruption Guidance Appliance: A Case Report. **Int J Environ Res Public Health**, 17, n. 10, May 20 2020.

SMYTH, R. S. D.; RYAN, F. S. Early treatment of class III malocclusion with facemask. **Evid Based Dent**, 18, n. 4, p. 107-108, Dec 22 2017.

SOUKI, B. Q.; NIERI, M.; PAVONI, C.; PAVAN BARROS, H. M. *et al.* Development and validation of a prediction model for long-term unsucces of early treatment of Class III malocclusion. **Eur J Orthod**, 42, n. 2, p. 200-205, Apr 1 2020.

TAUSCHE, E.; LUCK, O.; HARZER, W. Prevalence of malocclusions in the early mixed dentition and orthodontic treatment need. **Eur J Orthod**, 26, n. 3, p. 237-244, Jun 2004.

TOLLARO, I.; BACCETTI, T.; FRANCHI, L. Craniofacial changes induced by early functional treatment of Class III malocclusion. **Am J Orthod Dentofacial Orthop**, 109, n. 3, p. 310-318, Mar 1996.

VASILAKOS, G.; KONIARIS, A.; WOLF, M.; HALAZONETIS, D. *et al.* Early anterior crossbite correction through posterior bite opening: a 3D superimposition prospective cohort study. **Eur J Orthod**, 40, n. 4, p. 364-371, Jul 27 2018.

---

VAUGHN, G. A.; MASON, B.; MOON, H. B.; TURLEY, P. K. The effects of maxillary protraction therapy with or without rapid palatal expansion: a prospective, randomized clinical trial. **Am J Orthod Dentofacial Orthop**, 128, n. 3, p. 299-309, Sep 2005.

VEDOVELLO, S. A. S.; DE CARVALHO, A. L. M.; DE AZEVEDO, L. C.; SANTOS, P. R. D. *et al.* Impact of anterior occlusal conditions in the mixed dentition on oral health-related quality-of-life item levels: A multivariate analysis. **Angle Orthod**, Feb 24 2020.

WATKINSON, S.; HARRISON, J. E.; FURNESS, S.; WORTHINGTON, H. V. Orthodontic treatment for prominent lower front teeth (Class III malocclusion) in children. **Cochrane Database Syst Rev**, n. 9, p. Cd003451, Sep 30 2013.

WIEDEL, A. P.; BONDEMARK, L. Stability of anterior crossbite correction: a randomized controlled trial with a 2-year follow-up. **Angle Orthod**, 85, n. 2, p. 189-195, Mar 2015.

WOON, S. C.; THIRUVENKATACHARI, B. Early orthodontic treatment for Class III malocclusion: A systematic review and meta-analysis. **Am J Orthod Dentofacial Orthop**, 151, n. 1, p. 28-52, Jan 2017.

YANG, K. H. Frankel appliance type III: correct fabrication and case report of skeletal Class III malocclusion. **J Clin Pediatr Dent**, 20, n. 4, p. 281-292, Summer 1996.

YANG, X.; LI, C.; BAI, D.; SU, N. *et al.* Treatment effectiveness of Fränkel function regulator on the Class III malocclusion: a systematic review and meta-analysis. **Am J Orthod Dentofacial Orthop**, 146, n. 2, p. 143-154, Aug 2014.

YAVUZ, I.; HALICIOĞLU, K.; CEYLAN, I.; DAĞSUYU, I. M. *et al.* The effects of face mask therapy with and without rapid maxillary expansion in adolescent patients. **Aust Orthod J**, 28, n. 1, p. 63-71, May 2012.

ZHANG, W.; QU, H. C.; YU, M.; ZHANG, Y. The Effects of Maxillary Protraction with or without Rapid Maxillary Expansion and Age Factors in Treating Class III Malocclusion: A Meta-Analysis. **PLoS One**, 10, n. 6, p. e0130096, 2015.

---

---





# APPENDIX

---

---



**APPENDIX A – DECLARATION OF EXCLUSIVE USE OF THE ARTICLE IN  
DISSERTATION/THESIS**

We hereby declare that we are aware of the article “EFFECTS OF A PRE-FABRICATED CORRECTOR APPLIANCE IN THE EARLY TREATMENT OF ANTERIOR CROSSBITE IN CLASS III MALOCCLUSION” will be included in Dissertation of the student Gonzalo Paúl Velásquez Huilca and may not be used in other works of Graduate Programs at the Bauru Dental School, University of São Paulo.

Bauru, January 26<sup>TH</sup>, 2021.

Gonzalo Paúl Velásquez Huilca

**Author**



**Signature**

Guilherme Janson

**Author**



**Signature**



# **ANNEXES**

---

---



**ANNEX A. Ethics Committee approval, protocol number 24521419.6.0000.5417 (front)**

USP - FACULDADE DE  
ODONTOLOGIA DE BAURU DA  
USP



**PARECER CONSUBSTANCIADO DO CEP**

**DADOS DO PROJETO DE PESQUISA**

**Título da Pesquisa:** EFEITOS DO ORTHO-TAIN CLASS III APPLIANCE NO TRATAMENTO PRECOCE DA MÁ OCLUSÃO DE CLASSE III

**Pesquisador:** Gonzalo Paúl Velásquez Huilca

**Área Temática:**

**Versão:** 4

**CAAE:** 24521419.6.0000.5417

**Instituição Proponente:** Universidade de São Paulo - Faculdade de Odontologia de Bauru

**Patrocinador Principal:** Financiamento Próprio

**DADOS DO PARECER**

**Número do Parecer:** 4.022.856

**Apresentação do Projeto:**

Cinquenta e quatro pacientes entre 6 e 8 anos com má oclusão de Class III serão alocados em dois grupos de estudo. O grupo experimental consistirá em 27 pacientes que serão tratados com o Ortho-Tain Class III appliance e o grupo controle consistirá em 27 pacientes fornecidos pela AAOF Legacy Collection. Serão obtidas telerradiografias, de noma lateral, no início e no final do tratamento. Serão avaliadas as alterações esqueléticas e tegumentares.

**Objetivo da Pesquisa:**

O objetivo deste trabalho será realizar uma avaliação cefalométrica, das alterações decorrentes do tratamento precoce da má oclusão de Classe III associada à mordida cruzada anterior com o Ortho-Tain Class III Appliance.

**Avaliação dos Riscos e Benefícios:**

Estão adequados.

**Comentários e Considerações sobre a Pesquisa:**

As pendências solicitadas foram corrigidas.

**Considerações sobre os Termos de apresentação obrigatória:**

Estão adequados.

**Recomendações:**

Não se aplica.

**Endereço:** DOUTOR OCTAVIO PINHEIRO BRISOLLA 75 QUADRA 9  
**Bairro:** VILA NOVA CIDADE UNIVERSITARIA      **CEP:** 17.012-901  
**UF:** SP      **Município:** BAURU  
**Telefone:** (14)3235-8356      **Fax:** (14)3235-8356      **E-mail:** cep@fob.usp.br



**ANNEX A. Ethics Committee approval, protocol number 24521419.6.0000.5417 (verso).**

USP - FACULDADE DE  
ODONTOLOGIA DE BAURU DA  
USP



Continuação do Parecer: 4.022.856

**Conclusões ou Pendências e Lista de Inadequações:**

Projeto aprovado sem restrições de ordem ética.

**Considerações Finais a critério do CEP:**

Esse projeto foi considerado APROVADO na reunião ordinária do CEP de 06/05/2020, via Google Meet, devido à pandemia da COVID-19 e por orientações da CONEP, com base nas normas éticas da Resolução CNS 466/12. Ao término da pesquisa o CEP-FOB/USP exige a apresentação de relatório final. Os relatórios parciais deverão estar de acordo com o cronograma e/ou parecer emitido pelo CEP. Alterações na metodologia, título, inclusão ou exclusão de autores, cronograma e quaisquer outras mudanças que sejam significativas deverão ser previamente comunicadas a este CEP sob risco de não aprovação do relatório final. Quando da apresentação deste, deverão ser incluídos todos os TCLEs e/ou termos de doação assinados e rubricados, se pertinentes.

Este parecer foi elaborado baseado nos documentos abaixo relacionados:

Tipo Documento	Arquivo	Postagem	Autor	Situação
Informações Básicas do Projeto	PB_INFORMAÇÕES_BÁSICAS_DO_PROJETO_1433080.pdf	20/03/2020 16:18:31		Aceito
Outros	Respostas.pdf	20/03/2020 16:18:07	Gonzalo Paúl Velásquez Huilca	Aceito
Projeto Detalhado / Brochura Investigador	Projeto.pdf	20/03/2020 16:17:44	Gonzalo Paúl Velásquez Huilca	Aceito
TCLE / Termos de Assentimento / Justificativa de Ausência	TALE.pdf	20/03/2020 16:17:30	Gonzalo Paúl Velásquez Huilca	Aceito
TCLE / Termos de Assentimento / Justificativa de Ausência	TCLE.pdf	20/03/2020 16:17:21	Gonzalo Paúl Velásquez Huilca	Aceito
Parecer Anterior	PB_PARECER_CONSUBSTANCIADO_CEP_3912580.pdf	20/03/2020 16:17:06	Gonzalo Paúl Velásquez Huilca	Aceito
Orçamento	Orcamento.pdf	28/02/2020 14:02:52	Gonzalo Paúl Velásquez Huilca	Aceito
Cronograma	Cronograma.pdf	28/02/2020 14:01:20	Gonzalo Paúl Velásquez Huilca	Aceito
Declaração de Instituição e Infraestrutura	TermoDeAquiencia.pdf	18/12/2019 13:18:48	Gonzalo Paúl Velásquez Huilca	Aceito
Declaração de	DeclaracaoCompromissoPesquisador	18/12/2019	Gonzalo Paúl	Aceito

Endereço: DOUTOR OCTAVIO PINHEIRO BRISOLLA 75 QUADRA 9  
 Bairro: VILA NOVA CIDADE UNIVERSITARIA CEP: 17.012-901  
 UF: SP Município: BAURU  
 Telefone: (14)3235-8356 Fax: (14)3235-8356 E-mail: cep@fob.usp.br

**ANNEX A. Ethics Committee approval, protocol number 24521419.6.0000.5417 (front)**

USP - FACULDADE DE  
ODONTOLOGIA DE BAURU DA  
USP



Continuação do Parecer: 4.022.856

Pesquisadores	.pdf	13:17:22	Velásquez Huilca	Aceito
Folha de Rosto	FolhaDeRostro.pdf	24/10/2019 18:13:37	Gonzalo Paúl Velásquez Huilca	Aceito

**Situação do Parecer:**

Aprovado

**Necessita Apreciação da CONEP:**

Não

BAURU, 12 de Maio de 2020


---

Assinado por:  
Juliana Fraga Soares Bombonatti  
(Coordenador(a))

Endereço: DOUTOR OCTAVIO PINHEIRO BRISOLLA 75 QUADRA 9  
Bairro: VILA NOVA CIDADE UNIVERSITARIA CEP: 17.012-901  
UF: SP Município: BAURU  
Telefone: (14)3235-8356 Fax: (14)3235-8356 E-mail: cep@fob.usp.br

## ANNEX B. Informed consent for children

Página 1 de 1



**Universidade de São Paulo**  
**Faculdade de Odontologia de Bauru**  
 Departamento de Odontopediatria, Ortodontia e Saúde Coletiva  
 Disciplina de Ortodontia

**Termo de Assentimento**

Você está sendo convidado (a) a participar da pesquisa "Efeitos do Ortho-Tain Class III Appliance no tratamento precoce da má oclusão de Classe III". Seu dentista será o Gonzalo Velásquez, aqui na Faculdade de Odontologia de Bauru da Universidade de São Paulo. Se você concordar em participar:


1. Você comparecerá aqui na clínica de Ortodontia (mesmo lugar onde você está agora) e o seu responsável (pai, mãe) será informado sobre a sua participação neste estudo.
2. Você vai usar um aparelho feito de borracha e será instalado pelo dentista que vai te atender. Este aparelho vai corrigir seus dentes que estão fora da posição ou tortos. É bem fácil de usar porque você pode colocar e tirar da boca, não incomoda e não dói. No caso de sentir dor devido a alguma ferida ou lesão na boca, deve parar de usar o aparelho e falar seu pai ou mãe, para que eles informem ao dentista e uma solução será encontrada para que você continue usando o aparelho.
3. Você vai usar no primeiro mês durante 2 horas por dia; neste tempo, você terá que fazer um exercício com o aparelho e a língua. Deve empurrar com a língua os dentes de cima por 30 segundos e depois 30 segundos de descanso, repetindo por 6 vezes. E no segundo mês irá dormir com ele à noite mais as 2 horas por dia fazendo o mesmo exercício, até terminar o tratamento.
4. Quando instalado o aparelho na sua boca é possível que você sinta um pouco de desconforto principalmente ao falar, mas pode ficar tranquilo, porque isso é normal, pelo menos no primeiro mês (período de adaptação dos seus músculos e sua língua), depois você se acostumará e não terá mais este desconforto.
5. Para avaliar que o aparelho esteja guiando o nascimento de seus novos dentes, alguns procedimentos serão realizados, mas todos são muito simples e rápidos. Durante as consultas, vamos tirar 3 fotos de seu rosto e 5 de seus dentes (8 fotos no total) e serão protegidas para que não saibam que é você, quando publicarmos em trabalhos científicos, livros ou aulas.
6. Estes procedimentos de acompanhamento serão realizados durante 18 meses e cada consulta terá uma duração de 30 minutos. Depois de terminar o tratamento, você continuará vindo à clínica para avaliar seu crescimento. O primeiro controle será feito após 1 ano, o segundo após 3 anos e o último será após 5 anos.
7. No início e no final do tratamento, você deve realizar 2 radiografias chamadas panorâmica e telerradiografia. Essas radiografias nos ajudarão com seu problema, são muito fáceis de fazer e um profissional em radiografias nos ajudará a fazê-las.
8. Qualquer problema com o aparelho, como ele quebrar ou se perder, avise o seu responsável para ele conversar com o dentista responsável. Se você tiver alguma dúvida, pode me perguntar a qualquer momento, você não precisa participar da pesquisa se não quiser, não terá nenhum problema e receberá atendimento da mesma forma.
9. É muito importante que você me ajude a corrigir seus dentes porque o sucesso do tratamento depende de você e da sua COLABORAÇÃO 100%.

Sendo assim, após me explicarem e ter lido e entendido todas as informações deste texto, eu, \_\_\_\_\_ aceito participar da pesquisa "Efeitos do Ortho-Tain Class III Appliance no tratamento precoce da má oclusão de Classe III".

- ♦ Entendi as coisas boas que podem acontecer, mas que também posso sentir um pequeno desconforto no começo do tratamento.
- ♦ Entendi que posso dizer "SIM" e participar, mas que, a qualquer momento, posso dizer "NÃO" e desistir.
- ♦ Os pesquisadores tiraram minhas dúvidas e conversaram com os meus responsáveis. Recebi uma cópia deste termo de assentimento e concordo em participar da pesquisa.


Bauru, \_\_\_\_ de \_\_\_\_\_ de \_\_\_\_\_.

\_\_\_\_\_  
 Gonzalo Paúl Velásquez Huilca  
 Pesquisador Responsável



**SIM, EU CONCORDO!**

\_\_\_\_\_  
 Assinatura do participante



**NÃO, EU NÃO CONCORDO!**

---

Al. Dr. Octávio Pinheiro Brisolla, 9-75 – Bauru-SP – CEP 17012-901 – C.P. 73  
 e-mail: [vsragato@fob.usp.br](mailto:vsragato@fob.usp.br) – Fone/FAX (0xx14) 3235-8217  
<http://www.fob.usp.br>



**ANNEX C. Informed consent for children's legal guardians (front)**

**Universidade de São Paulo**  
**Faculdade de Odontologia de Bauru**  
 Departamento de Odontopediatria, Ortodontia e  
 Saúde Coletiva

Página 1 de 2

**Termo de Consentimento Livre e Esclarecido (Ao responsável do participante)**

O menor sob sua responsabilidade está sendo convidado a participar como voluntário da pesquisa intitulada "Efeitos do Ortho-Tain Class III Appliance no tratamento precoce da má oclusão de Classe III". A pesquisa será realizada por mim Gonzalo Paúl Velásquez Huilca, mestrando em Ortodontia na Faculdade de Odontologia de Bauru da Universidade de São Paulo, sob orientação do Prof. Dr. Guilherme dos Reis Pereira Janson.

Esta pesquisa tem como objetivo principal avaliar as alterações produzidas pelo tratamento da má oclusão de Classe III (o queixo está posicionado para frente), associada à mordida cruzada anterior, utilizando um aparelho feito de borracha, chamado Ortho-Tain Class III.

Caso aceite participar o menor sob sua responsabilidade deverá usar o aparelho da seguinte maneira: o primeiro mês consistirá no uso durante duas horas por dia (neste tempo pode ter problemas para se adaptar ao aparelho), e o segundo mês será utilizado para dormir mais as duas horas usadas no dia (criança já adaptada ao uso do aparelho). É importante salientar que quanto mais tempo o aparelho for usado mais ajudará na correção da má oclusão, seguindo as instruções adequadas que serão transmitidas pelo pesquisador responsável.

Na primeira consulta, será instalado o aparelho de maneira simples. O procedimento não dói. Entretanto, após sua instalação a criança pode sentir certo desconforto principalmente para falar, porém suportável, pois é um período de adaptação para a língua e para a musculatura.

O aparelho a ser utilizado tem como **benefício** a melhora da estética e autoestima do paciente e em relação aos **riscos** do uso, pode-se causar uma intolerância ou alergia ao material (borracha), também ao longo dos primeiros meses de tratamento pode-se haver um desconforto na boca, ocasionando ulcerações (feridas) e por consequência dor localizada. Se algum desses problemas acontecer o participante deverá informar ao seu pai/mãe/responsável e interromper o uso do aparelho automaticamente e entrará em contato com o responsável da pesquisa para uma melhor avaliação e solução na Clínica de Ortodontia da FOB-USP. Em caso de não eficácia do tratamento, juntamente a os outros fatores limitantes, novos tratamentos serão propostos.

O menor com o auxílio do responsável, serão orientados a realizar um exercício diário com a língua pressionando o aparelho na boca, pelo menos uma vez durante 3 minutos. O exercício consiste em pressionar com a língua o espaço reservado para ela no aparelho na direção dos dentes de cima por 30 segundos e depois 30 segundos de descanso, repetindo por 8 vezes. Este exercício estimulará o desenvolvimento do osso onde estão localizados os dentes superiores, ajudando a corrigir a má oclusão.

Quando o aparelho não está sendo usado, deve estar dentro de sua caixa. Não deve estar perto de animais como cachorros e deve ser higienizado com a escova de dentes da criança pelo menos uma vez ao dia. Não deve ser enviado à escola com o aparelho com o uso do aparelho estritamente em casa.

As consultas durante o tratamento serão realizadas mensalmente, com um tempo aproximado de 30 minutos, durante 12 a 18 meses (tempo médio do tratamento) e o sucesso deste dependerá da colaboração da criança e do uso constante. Como explicado anteriormente, o uso correto do aparelho permitirá a correção da má oclusão de uma maneira rápida e simples.

Em cada consulta de atendimento o pesquisador responsável realizará fotos da face e da boca, totalizando 8 fotos, este procedimento é rápido e fazem parte da rotina odontológica, apresentando apenas mínimo desconforto. A identificação do paciente será protegida nestas fotografias, em futuras publicações em artigos científicos, apresentações de trabalhos em congressos, aulas, livros, etc.

É importante salientar que o menor de sua responsabilidade após finalizado o tratamento será convidado a retomar após 1 ano, 3 anos e 5 anos; para o acompanhamento do desenvolvimento da oclusão e caso apresente a necessidade de algum outro novo tratamento, o participante será encaminhado para o sistema de Triagem da Faculdade de Odontologia de Bauru para que seja avaliado e encaminhado a outros departamentos. Lembrando que durante todo período de acompanhamento, o menor poderá ser atendido em âmbito emergencial pelo pesquisador caso ocorra algum problema com o aparelho, independente do motivo. Dessa maneira, será proporcionada uma estabilidade aceitável dos resultados obtidos durante o tratamento ortodôntico.

Todos os procedimentos clínicos serão realizados pelo próprio pesquisador responsável, na clínica de Ortodontia da Faculdade de Odontologia de Bauru, Universidade de São Paulo. Em relação aos custos de "transporte público", será ressarcido qualquer gasto do participante e acompanhante em cada um dos controles durante as visitas à clínica de Ortodontia da FOB-USP. É garantida a indenização em casos de danos que ocorram decorrentes dos procedimentos empregados nesta pesquisa.

Tanto no início quanto no final do tratamento, o paciente deve realizar uma radiografia panorâmica e uma telerradiografia, embora os raios-x estejam ligados a um risco ligeiramente aumentado de câncer, existe um risco extremamente baixo de efeitos colaterais de curto prazo. No entanto, fornecem uma dose tão baixa de radiação que não se acredita que causem problemas de saúde imediatos. Essas radiografias nos ajudarão a diagnosticar o problema, monitorar a progressão do tratamento e finalmente comparar os resultados obtidos.

Al. Dr. Octávio Pinheiro Brisolla, 9-75 – Bauru-SP – CEP 17012-901 – C.P. 73

e-mail: [veragato@fob.usp.br](mailto:veragato@fob.usp.br) – Fone/FAX (0xx14) 3235-8217

<http://www.fob.usp.br>

Rubrica do Responsável do participante:

Rubrica do Pesquisador Responsável:

## ANNEX C. Informed consent for children's legal guardians (verso)



Universidade de São Paulo  
Faculdade de Odontologia de Bauru

Página 2 de 2

Departamento de Odontopediatria, Ortodontia e  
Saúde Coletiva

Além disso, ao final do estudo o menor sob sua responsabilidade terá garantido o acompanhamento e/ou tratamento ortodôntico complementar (caso os dentes estejam desalinhados por conta exclusivamente da "recidiva") e estará disposto aos melhores métodos preventivos, diagnósticos e terapêuticos que se demonstrarem eficazes, por parte da Instituição patrocinadora.

É de extrema importância que você saiba que a sua privacidade e do menor sob sua responsabilidade serão respeitadas. Ou seja, o seu nome, o nome do menor, ou qualquer outro dado que possa, de qualquer forma, identificá-los, será mantido em sigilo. O menor poderá deixar de participar da pesquisa a qualquer momento sem sofrer prejuízos, retirando, então, seu consentimento, sem precisar se justificar. Para qualquer questionamento futuro, você também ficará com uma cópia deste termo de consentimento livre e esclarecido.

O pesquisador responsável envolvido com a referida pesquisa é **Gonzalo Paúl Velásquez Huilca** e com ele você poderá manter contato via e-mail ([dr.gonzalo.orto@usp.br](mailto:dr.gonzalo.orto@usp.br)) ou telefone (14) 98111-1149.

É assegurada a assistência durante toda a pesquisa, bem como será garantido o livre acesso a todas as informações e esclarecimentos adicionais sobre o estudo. Pelo presente instrumento que atende às exigências legais, o(a) Sr.(a) \_\_\_\_\_, responsável pelo menor \_\_\_\_\_, portador da cédula de identidade \_\_\_\_\_,

após leitura minuciosa das informações constantes neste TERMO DE CONSENTIMENTO LIVRE E ESCLARECIDO, devidamente explicada pelos profissionais em seus mínimos detalhes, ciente dos serviços e procedimentos aos quais será submetido, não restando quaisquer dúvidas a respeito do lido e explicado, DECLARA e FIRMA seu CONSENTIMENTO LIVRE E ESCLARECIDO concordando em participar da pesquisa proposta. Fica claro que o participante da pesquisa, pode a qualquer momento retirar seu CONSENTIMENTO LIVRE E ESCLARECIDO e deixar de participar desta pesquisa e ciente de que todas as informações prestadas tornar-se-ão confidenciais e guardadas por força de sigilo profissional (Cap. III, Art. 9º do Código de Ética Odontológica).

Por fim, como pesquisador responsável pela pesquisa, DECLARO o cumprimento do disposto na Resolução CNS nº 466 de 2012, contidos nos itens IV.3 e IV.5.a e, na íntegra com a resolução CNS nº 466 de dezembro de 2012.

Por estarmos de acordo com o presente termo o firmamos em duas vias igualmente válidas (uma via para o participante da pesquisa e outra para o pesquisador) que serão rubricadas em todas as suas páginas e assinadas ao seu término, conforme o disposto pela Resolução CNS nº 466 de 2012, itens IV.3.f e IV.5.d.

Bauru, \_\_\_\_ de \_\_\_\_\_ de \_\_\_\_\_.

\_\_\_\_\_  
Gonzalo Paúl Velásquez Huilca  
Pesquisador Responsável

\_\_\_\_\_  
Nome/Assinatura do  
Responsável pelo participante

O Comitê de Ética em Pesquisa – CEP, organizado e criado pela FOB-USP, em 29/06/98 (Portaria GD/0698/FOB), previsto no item VII da Resolução nº 466/12 do Conselho Nacional de Saúde do Ministério da Saúde (publicada no DOU de 13/06/2013), é um Colegiado interdisciplinar e independente, de relevância pública, de caráter consultivo, deliberativo e educativo, criado para defender os interesses dos participantes da pesquisa em sua integridade e dignidade e para contribuir no desenvolvimento da pesquisa dentro de padrões éticos.

Qualquer denúncia e/ou reclamação sobre sua participação na pesquisa poderá ser reportada a este CEP:

**Horário e local de funcionamento:**

Comitê de Ética em Pesquisa  
Faculdade de Odontologia de Bauru-USP - Prédio da Pós-Graduação (bloco E - pavimento superior), de segunda à sexta-feira, no horário das 14hs às 17h30.  
Alameda Dr. Octávio Pinheiro Brisolla, 9-75  
Vila Universitária – Bauru – SP – CEP 17012-901  
Telefone/FAX(14)3235-8356  
e-mail: [cep@fob.usp.br](mailto:cep@fob.usp.br)

Al. Dr. Octávio Pinheiro Brisolla, 9-75 – Bauru-SP – CEP 17012-901 – C.P. 73  
e-mail: [veragato@fob.usp.br](mailto:veragato@fob.usp.br) – Fone/FAX (0xx14) 3235-8217  
<http://www.fob.usp.br>